

Interventional cardiology procedures involving eye lens exposure



30/01/2020

What is interventional cardiology?



Electrophysiology



Cath Lab



1958: the first pacemaker implantation

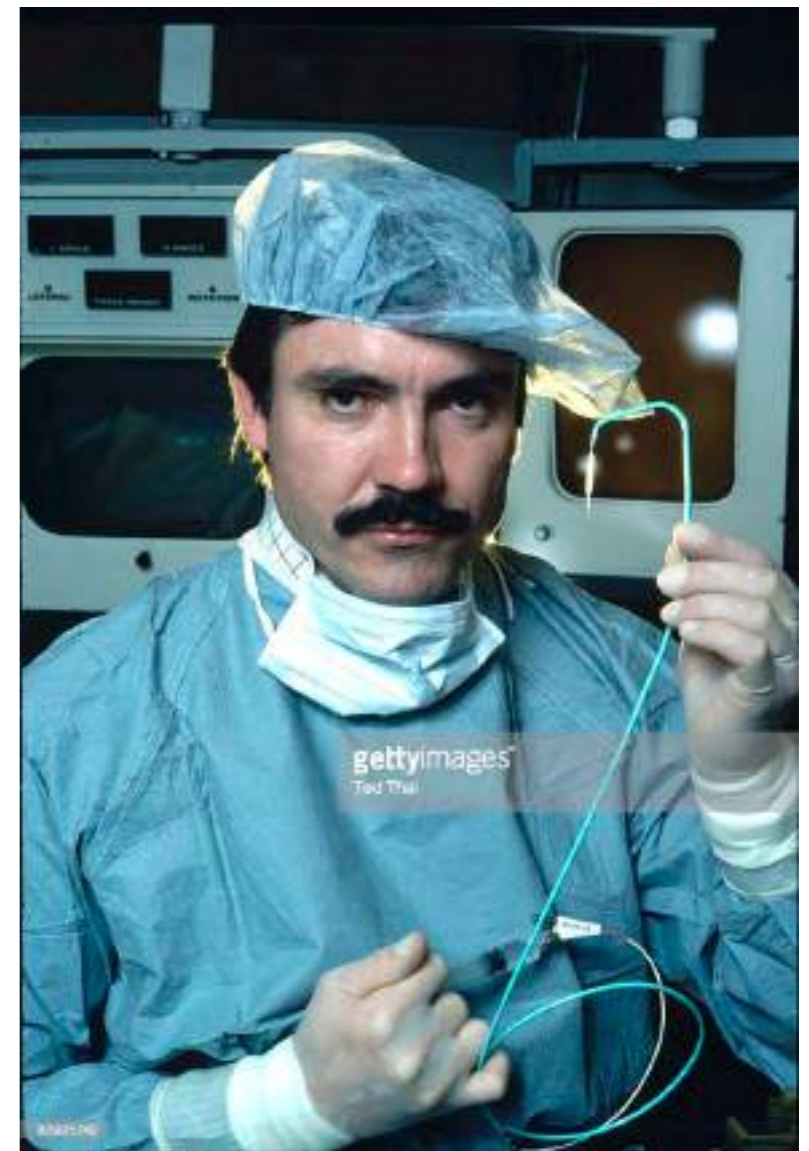


Dr Ake Senning and team done first successful pacemaker implantation to a patient name Arne Iarsson with Stroke-Adam syndrome

40 years ago: the first coronary angioplasty



Andreas Gruentzig presenting poster at the 1976 AHA
Andreas Gruentzig 1st Performer Angioplasty in 1974
In 1977 performed 1st coronary angioplasty



Polyvinyl chloride balloon catheter
with short guidewire attached to its tip.

Attività radiodiagnostica complementare:


Nella comune pratica clinica **molti specialisti ricorrono all'ausilio delle apparecchiature di diagnostica per immagini che emettono radiazioni ionizzanti** (es. **cardiologi, chirurghi vascolari, gastroenterologi, ortopedici, urologi, ecc.**). **Le attività radiodiagnostiche complementari si definiscono pertanto come quelle di ausilio diretto al medico chirurgo o all'odontoiatra per lo svolgimento di specifici interventi di carattere strumentale propri della disciplina, purché contestuali, integrate e indilazionabili, rispetto all'espletamento della procedura specialistica (art. 2 comma 1b DL.vo 187/2000) (2).**

La responsabilità dell'atto radiologico nell'utilizzo complementare e della relativa esposizione del paziente ricade sul medico specialista competente per la specifica procedura (DL.vo 187/2000 art. 2, 5-8, 12)

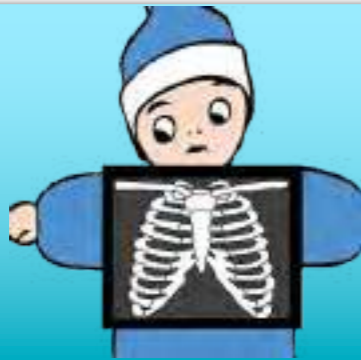Professional figures involved in interventional radiology



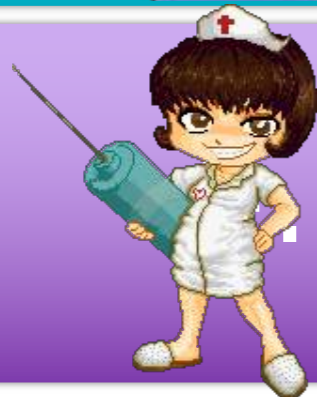
- doctor



- medical physicist



- radiologist technician




- nurse

Electrophysiology



Pacemaker



Catheter

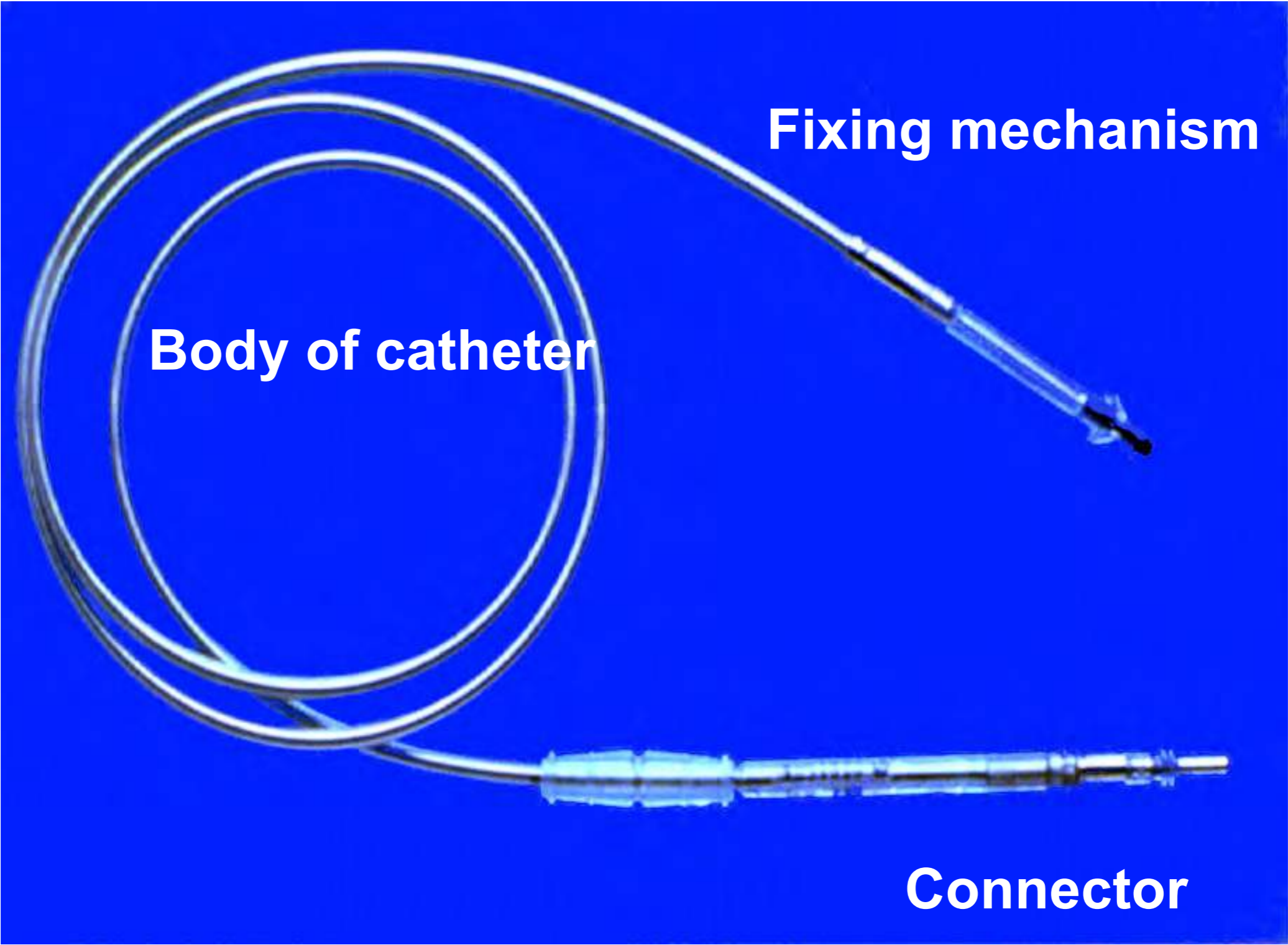


Device



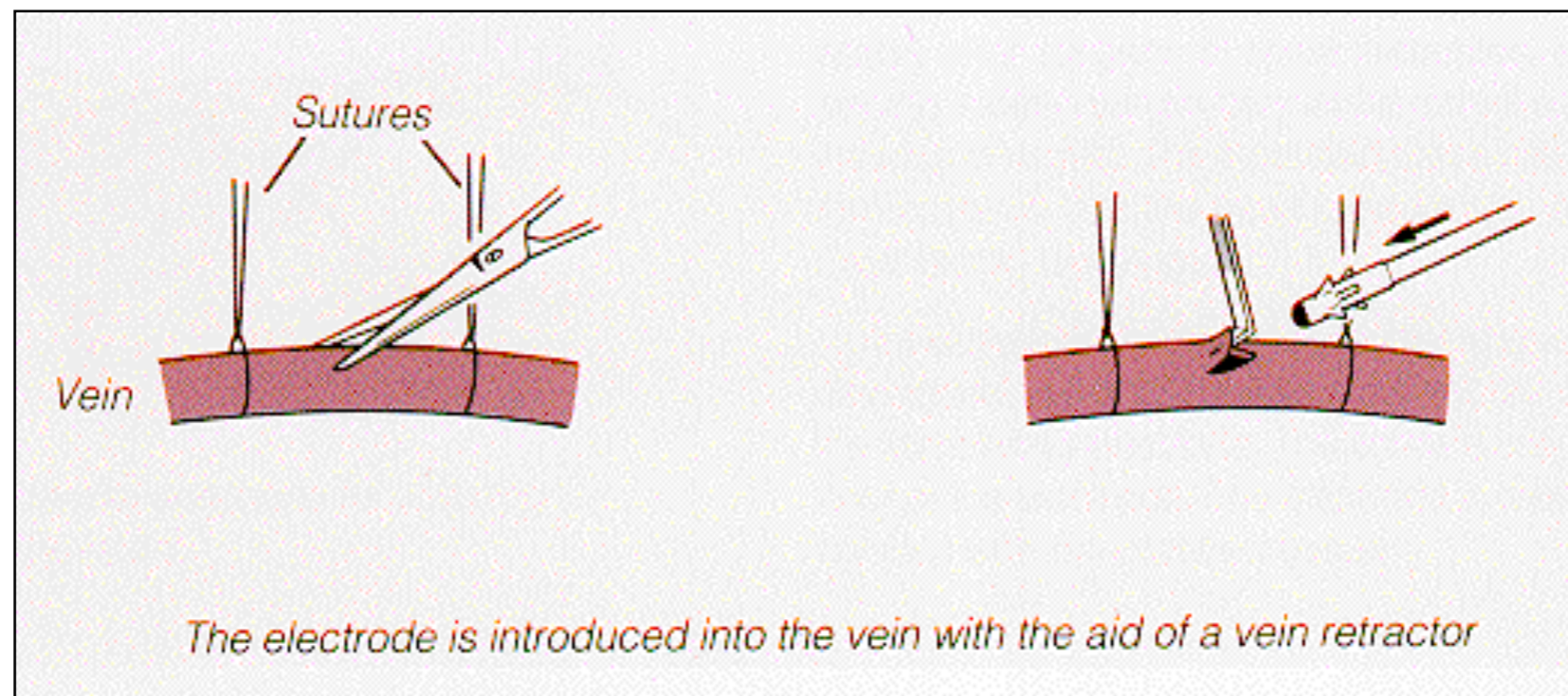
Programmer

Catheter




IMPLANTATION (Transvenous access)

- **Puncture of subclavian vein**
- **Puncture of axillary vein**
- **Isolation of cephalic vein**




Unicameral device

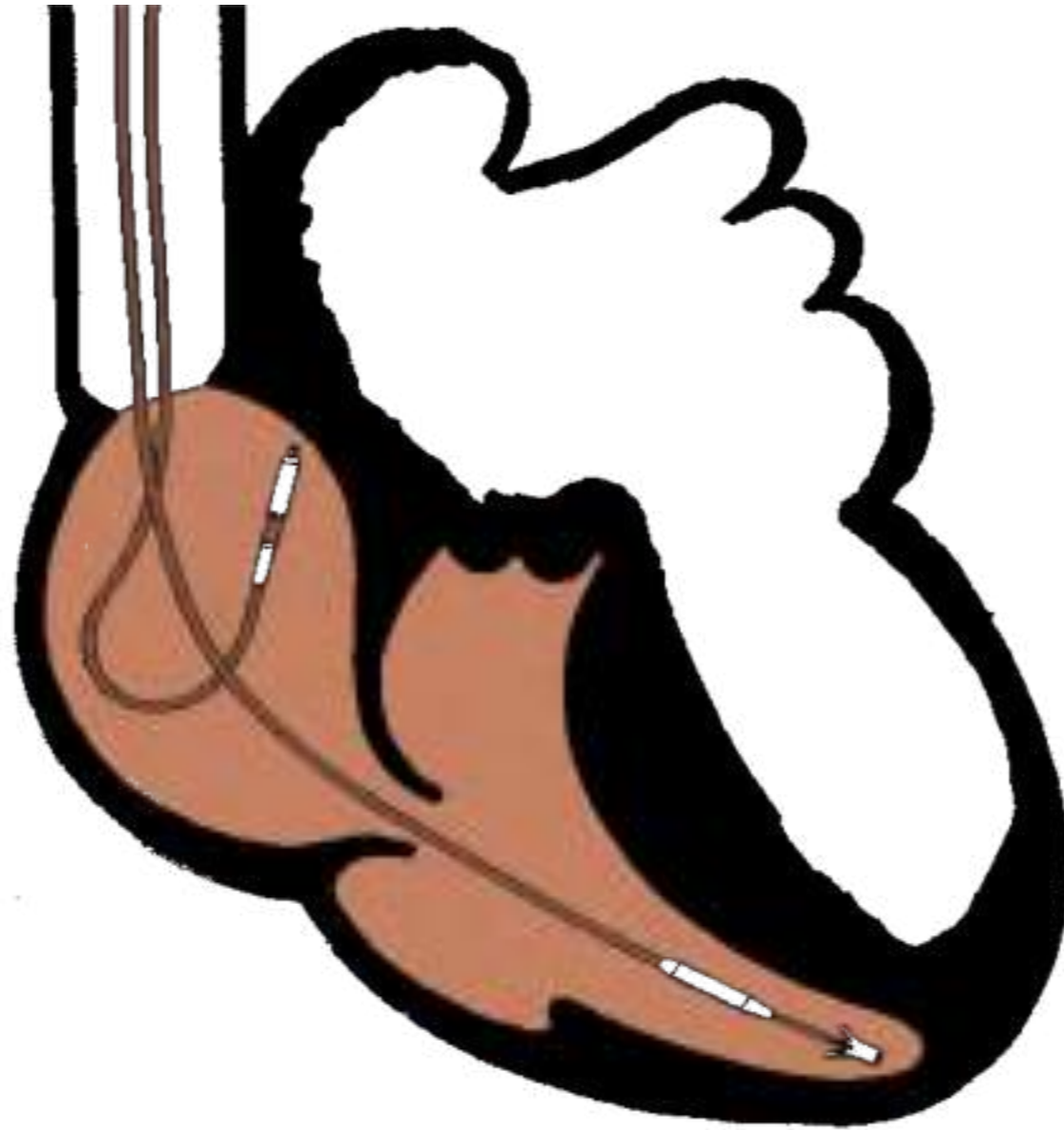
Atrial stimulation



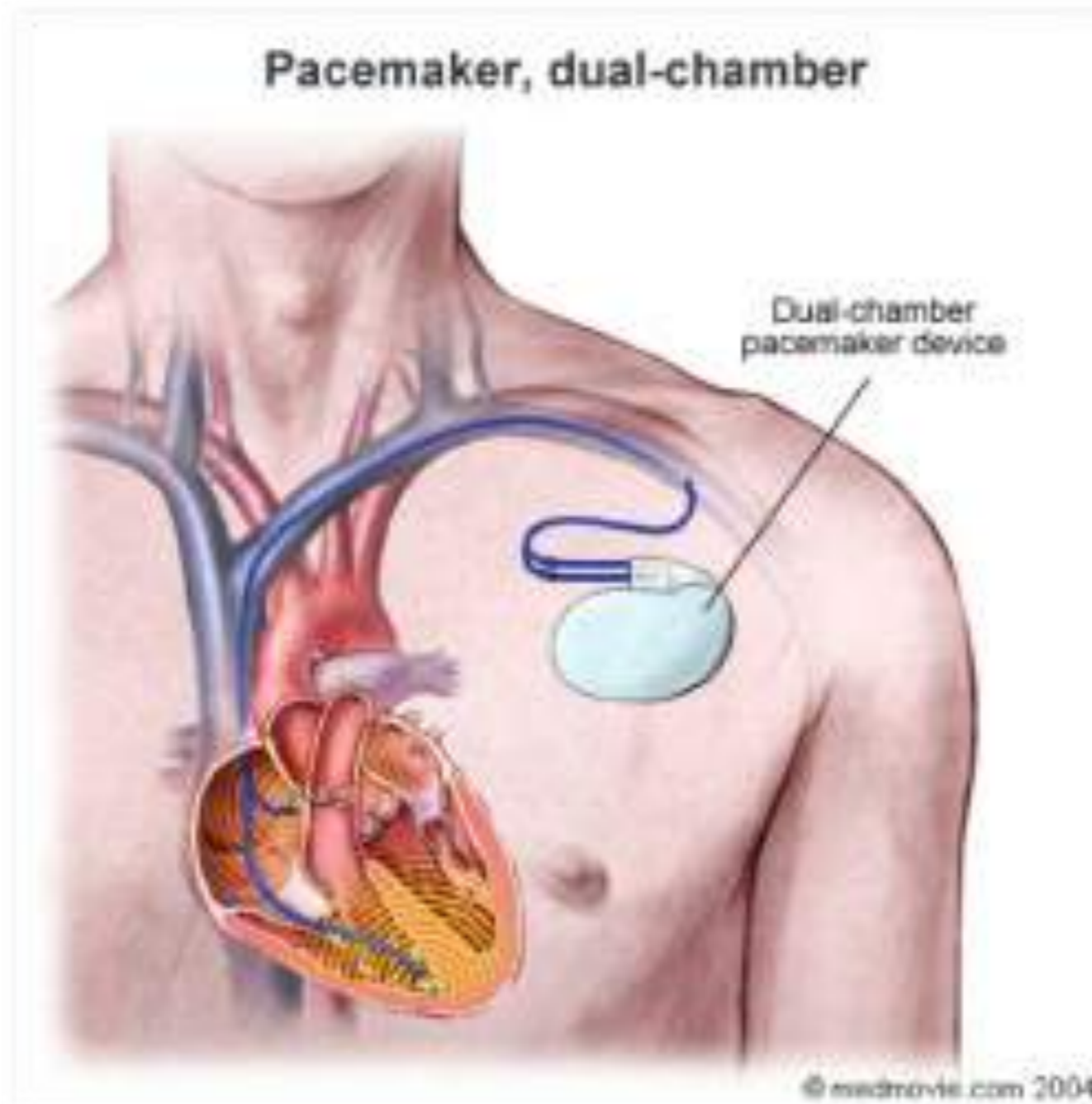
Ventricular stimulation



Dual-chamber device



Pace-maker



What is AICD?

Pacemaker



+



=

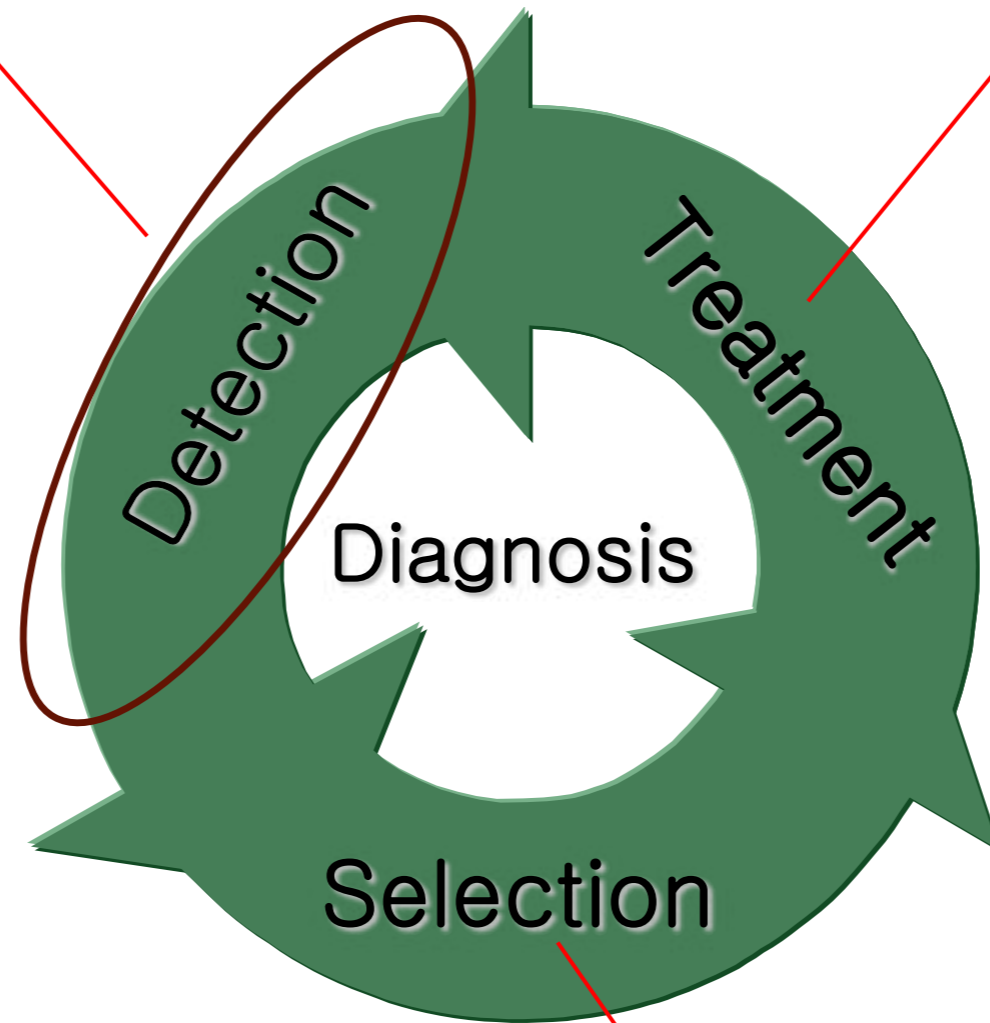
AICD



How ICD works?

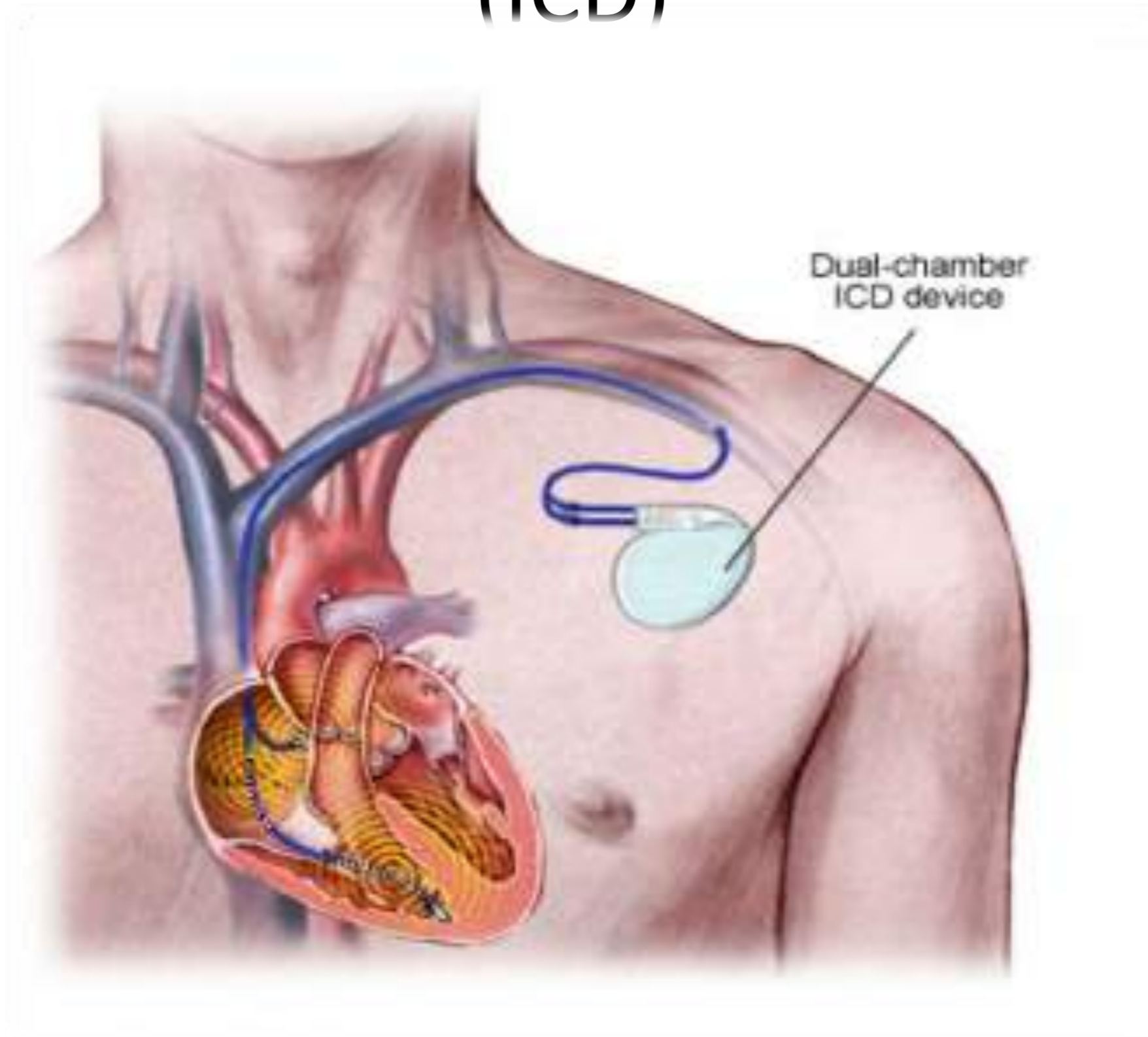
- Heart rate
- Morfology
- Duration

- ATP
- Shock

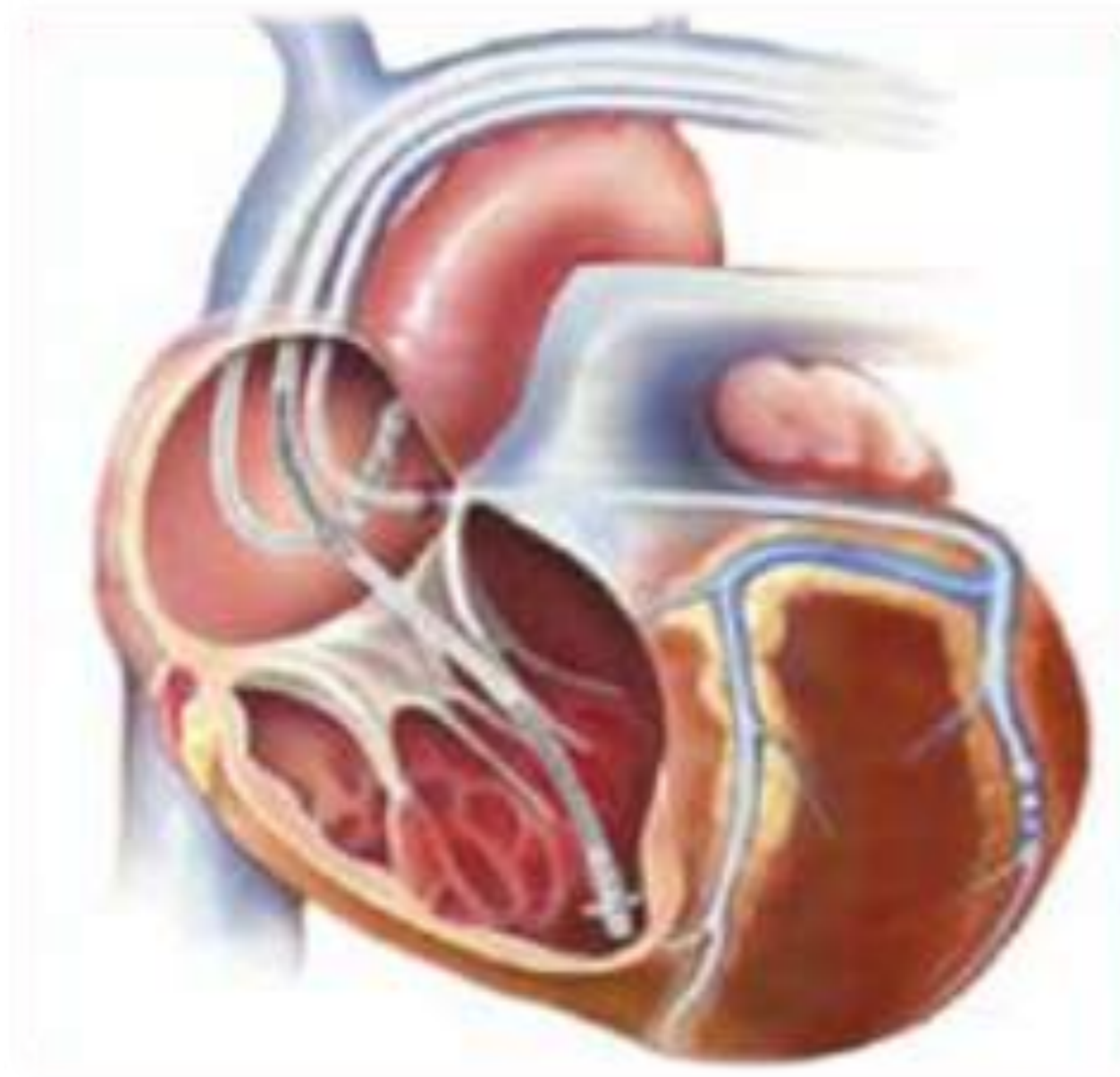


Algorithm of discrimination

Implantable-cardioverter defibrillator (ICD)



Cardiac Resynchronization Therapy (CRT)



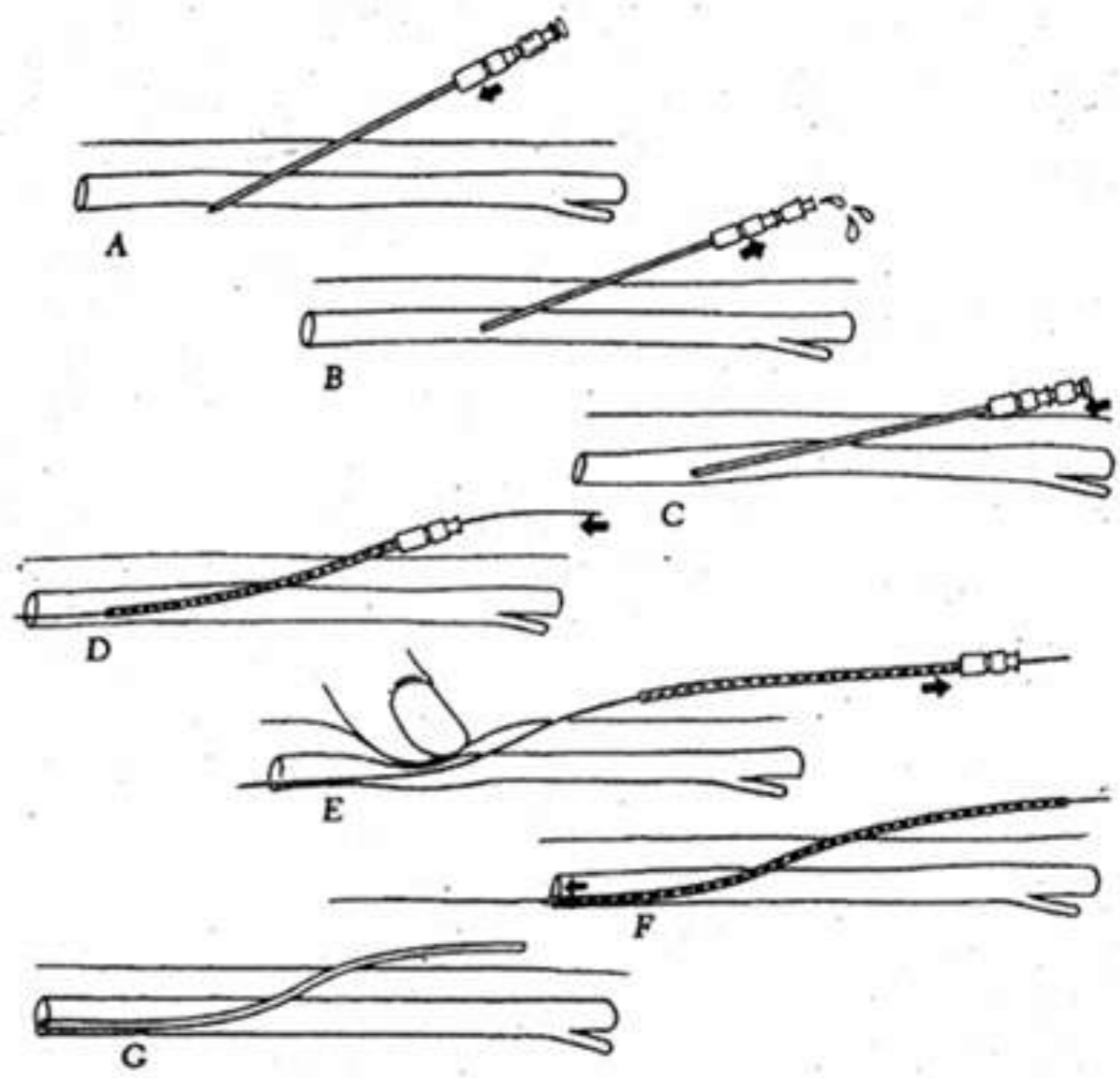
ABLATION

Transvenous access

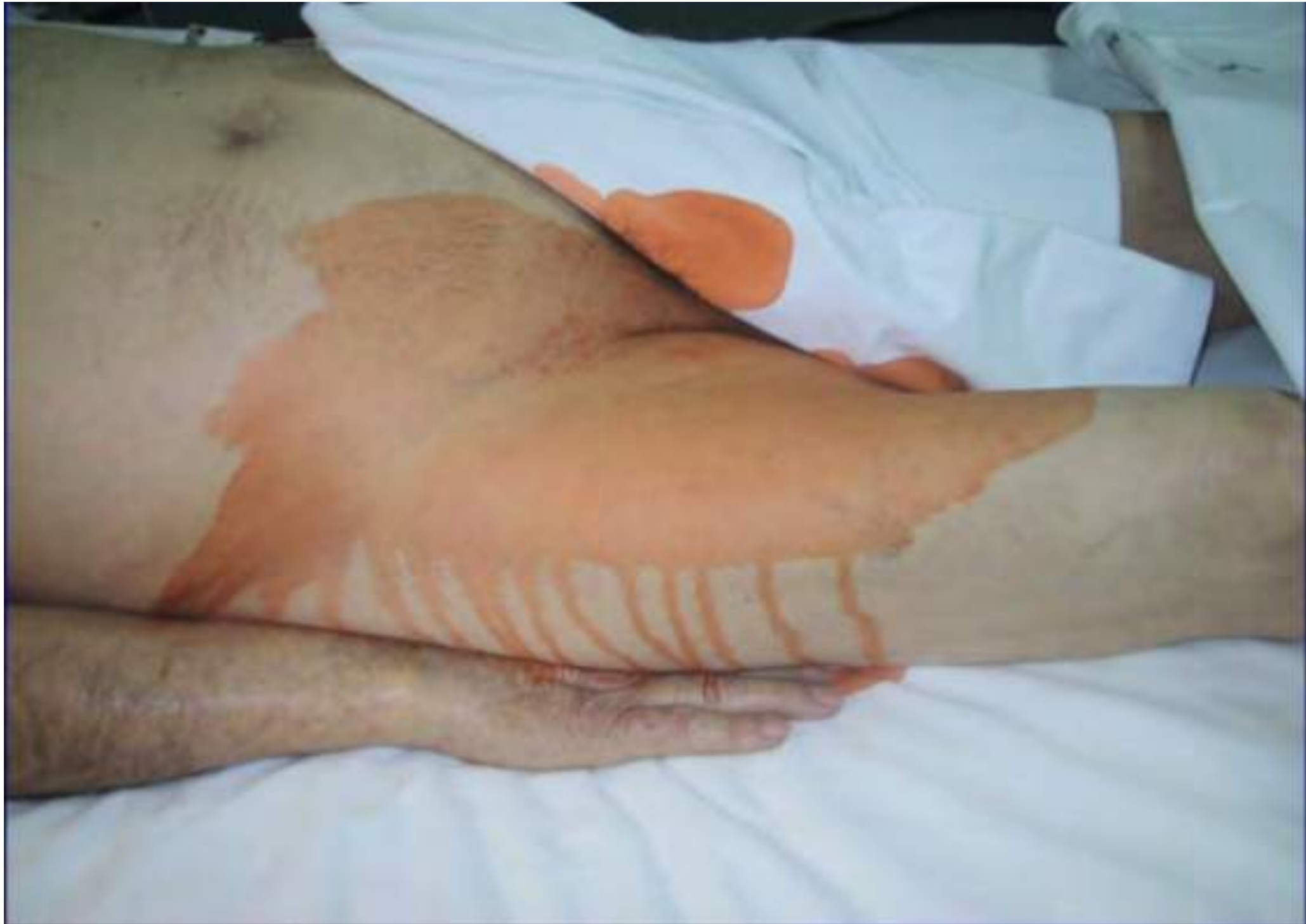Sheath

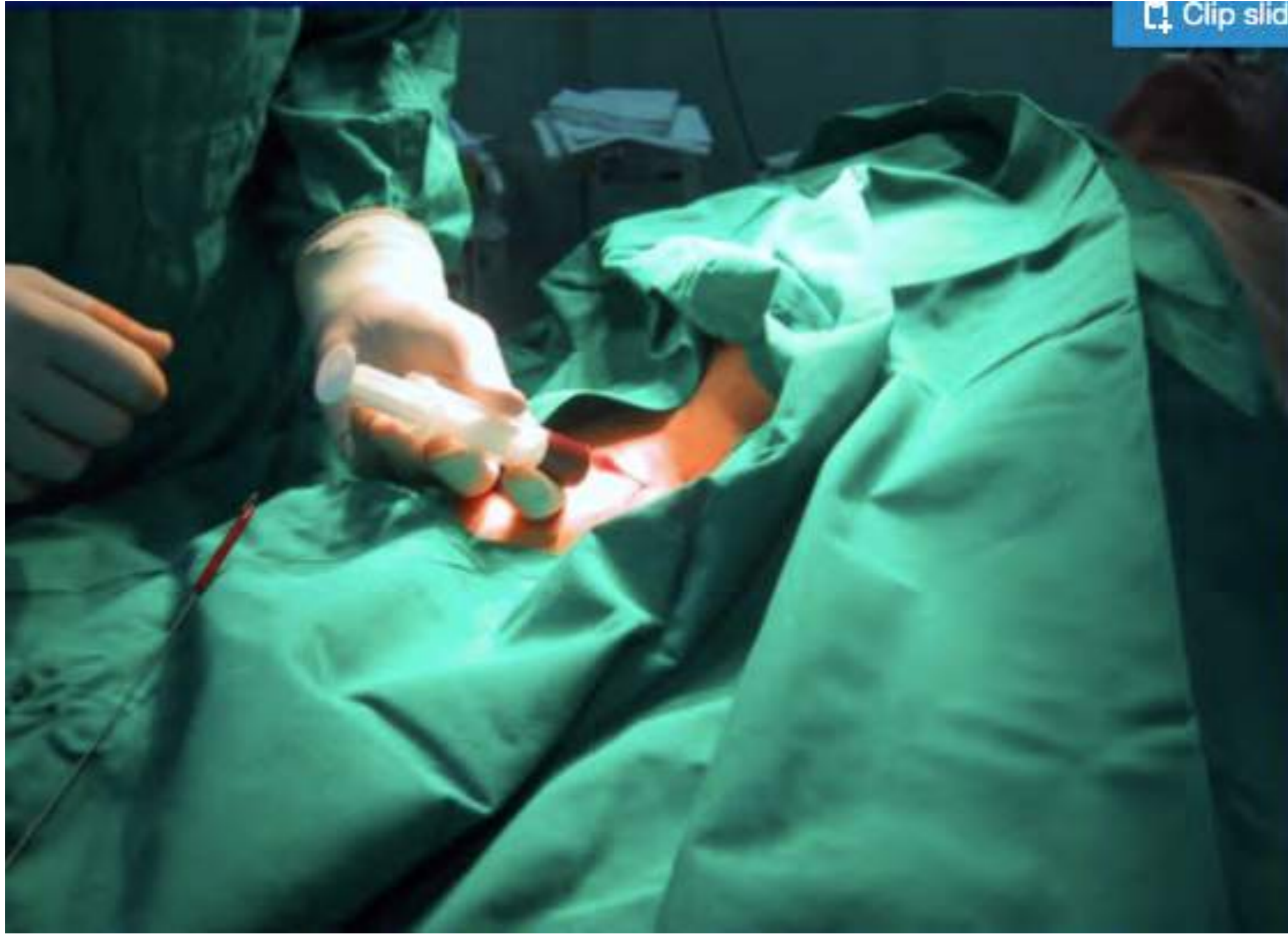

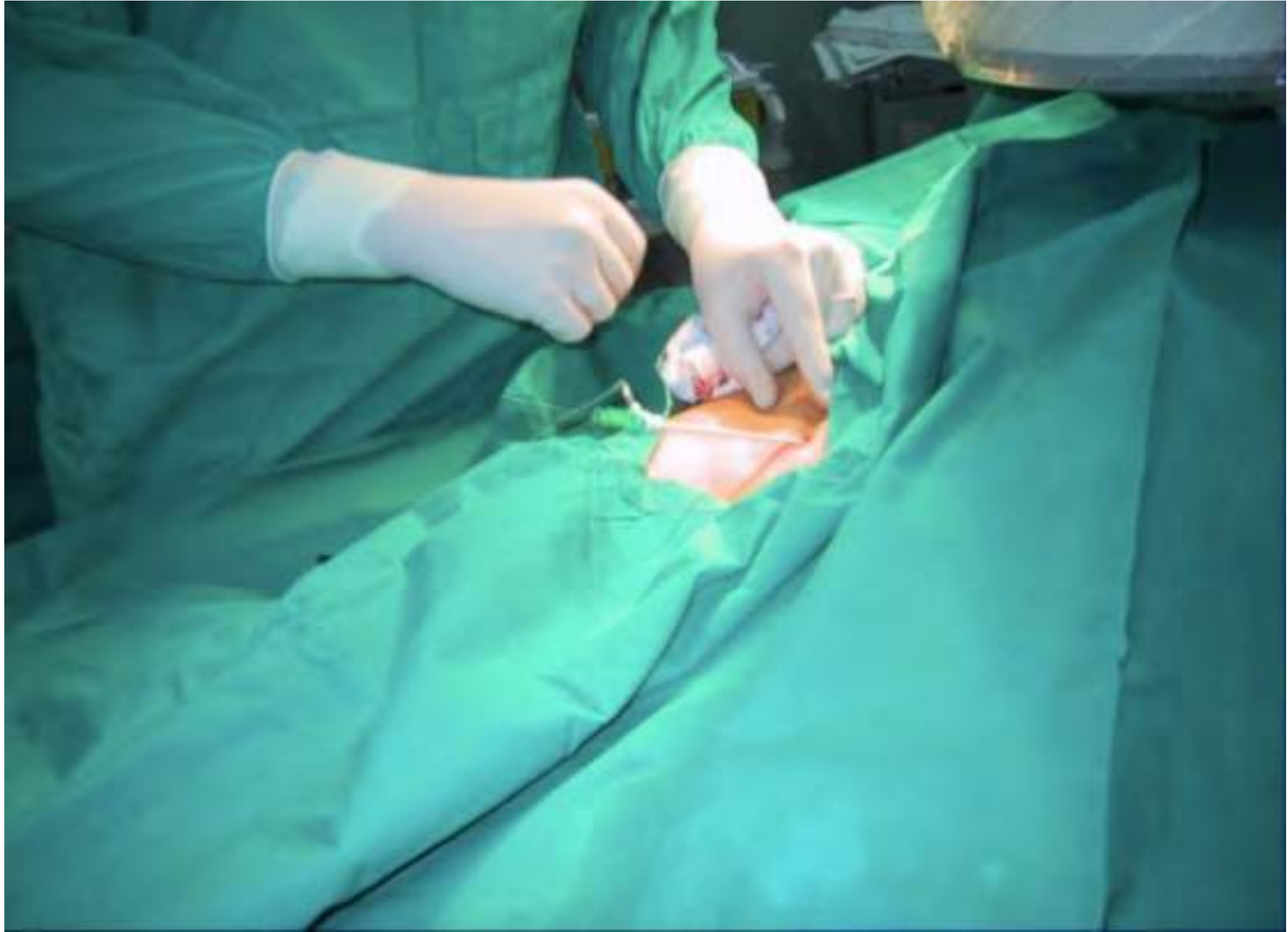technique

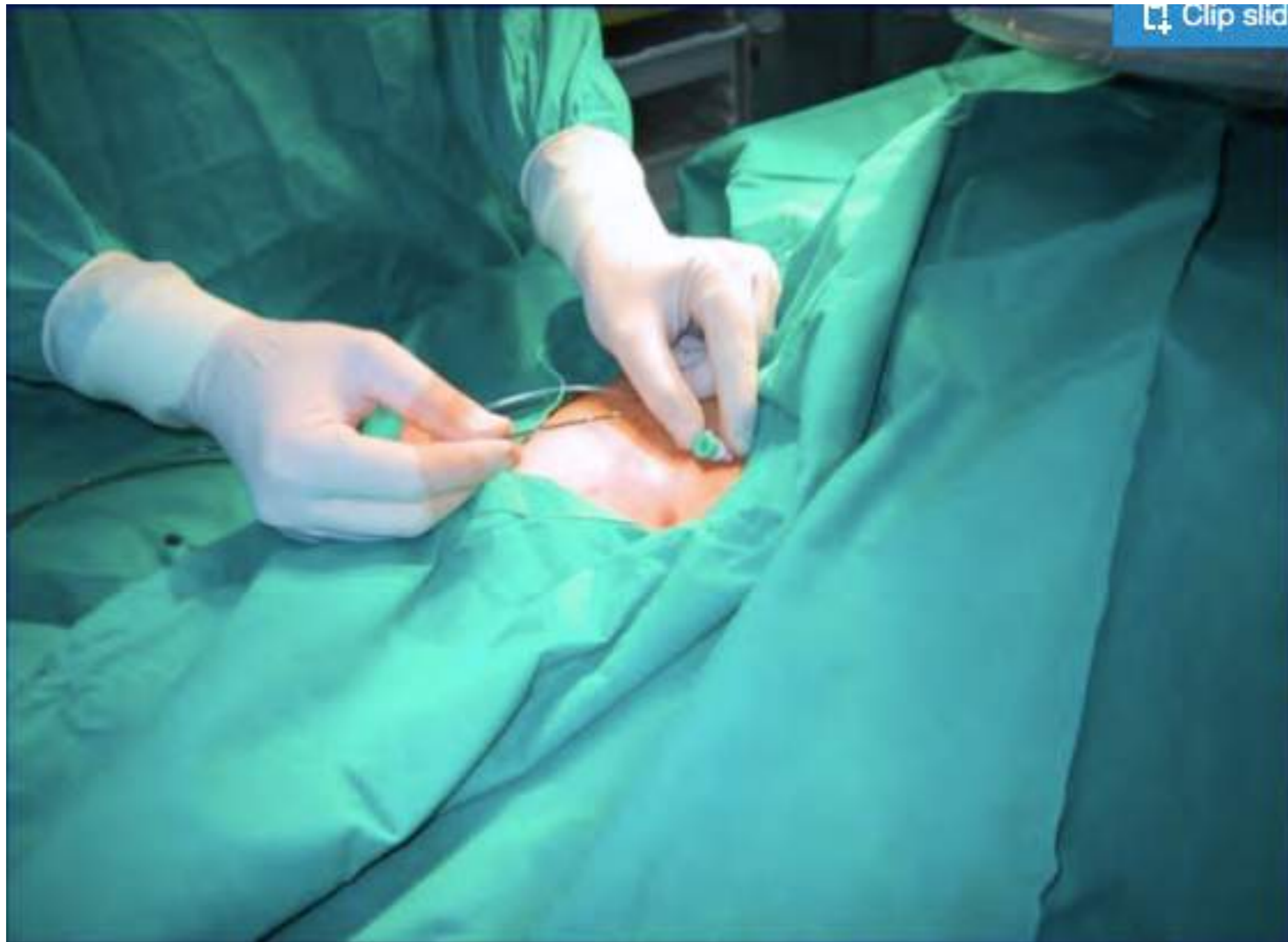


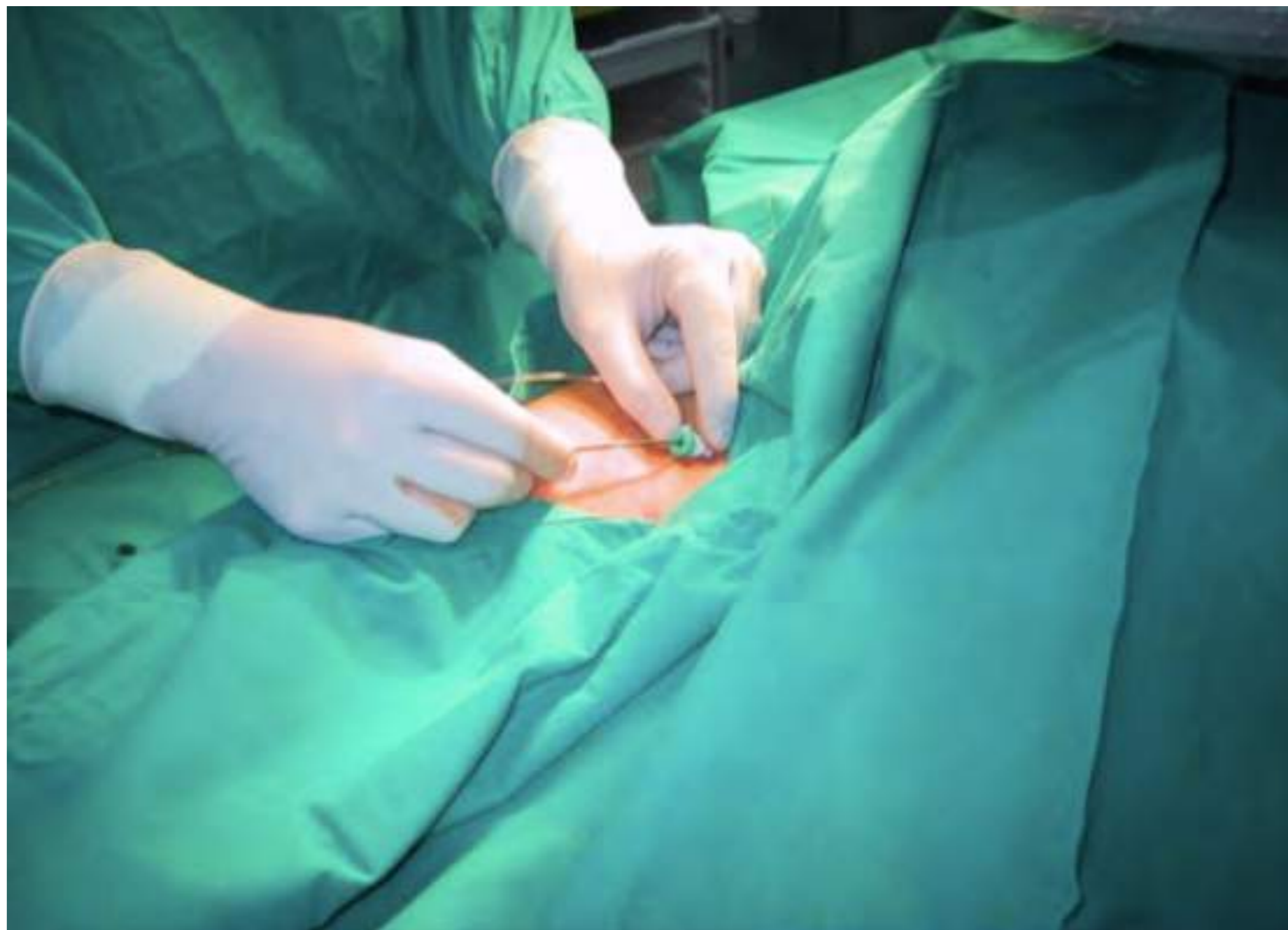Transvenous access



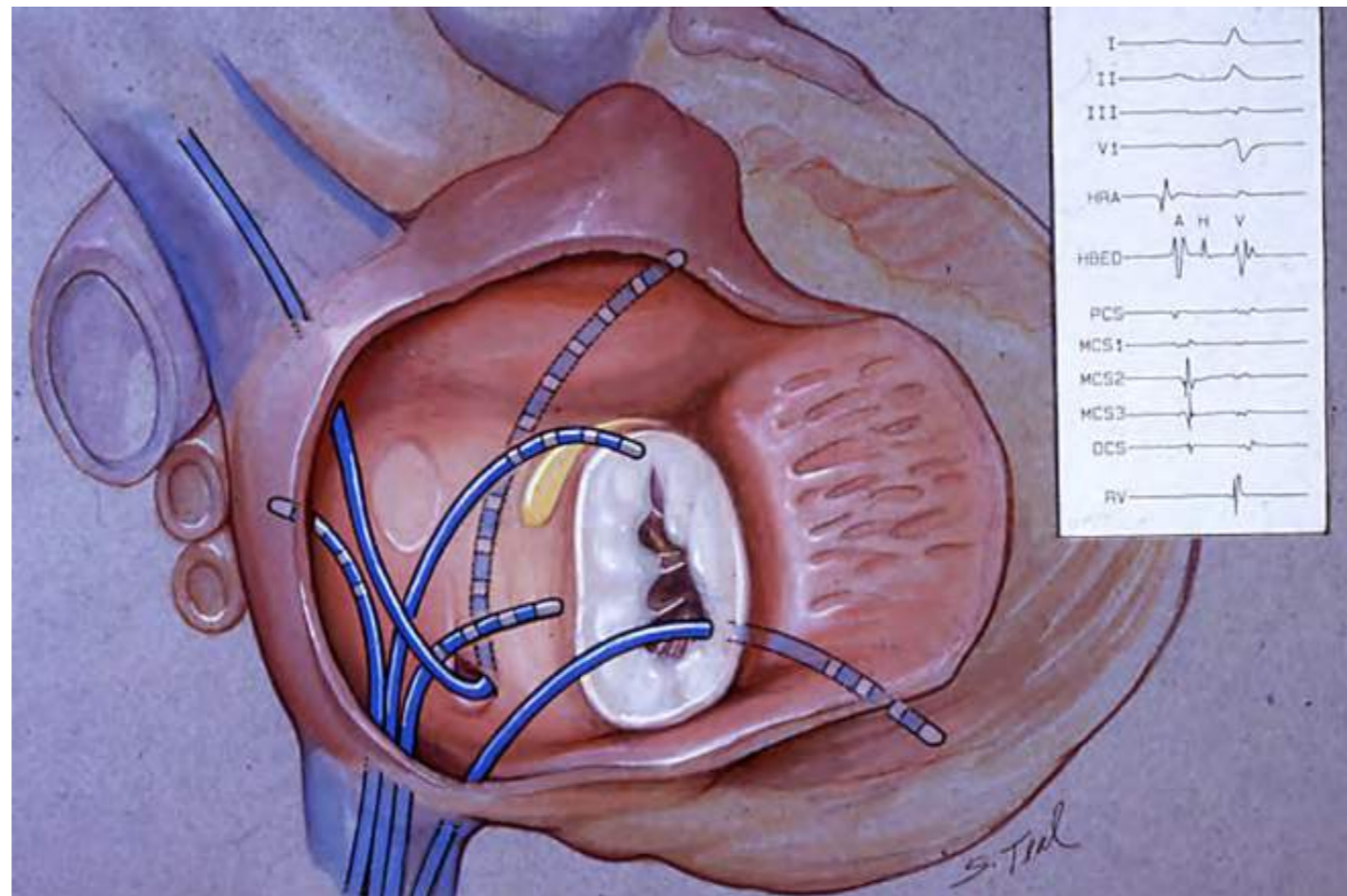
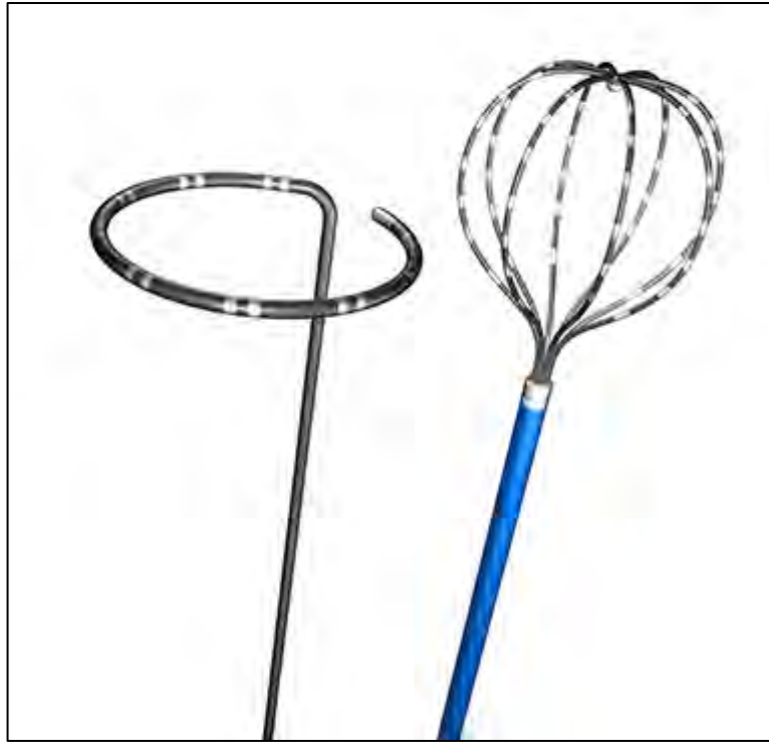

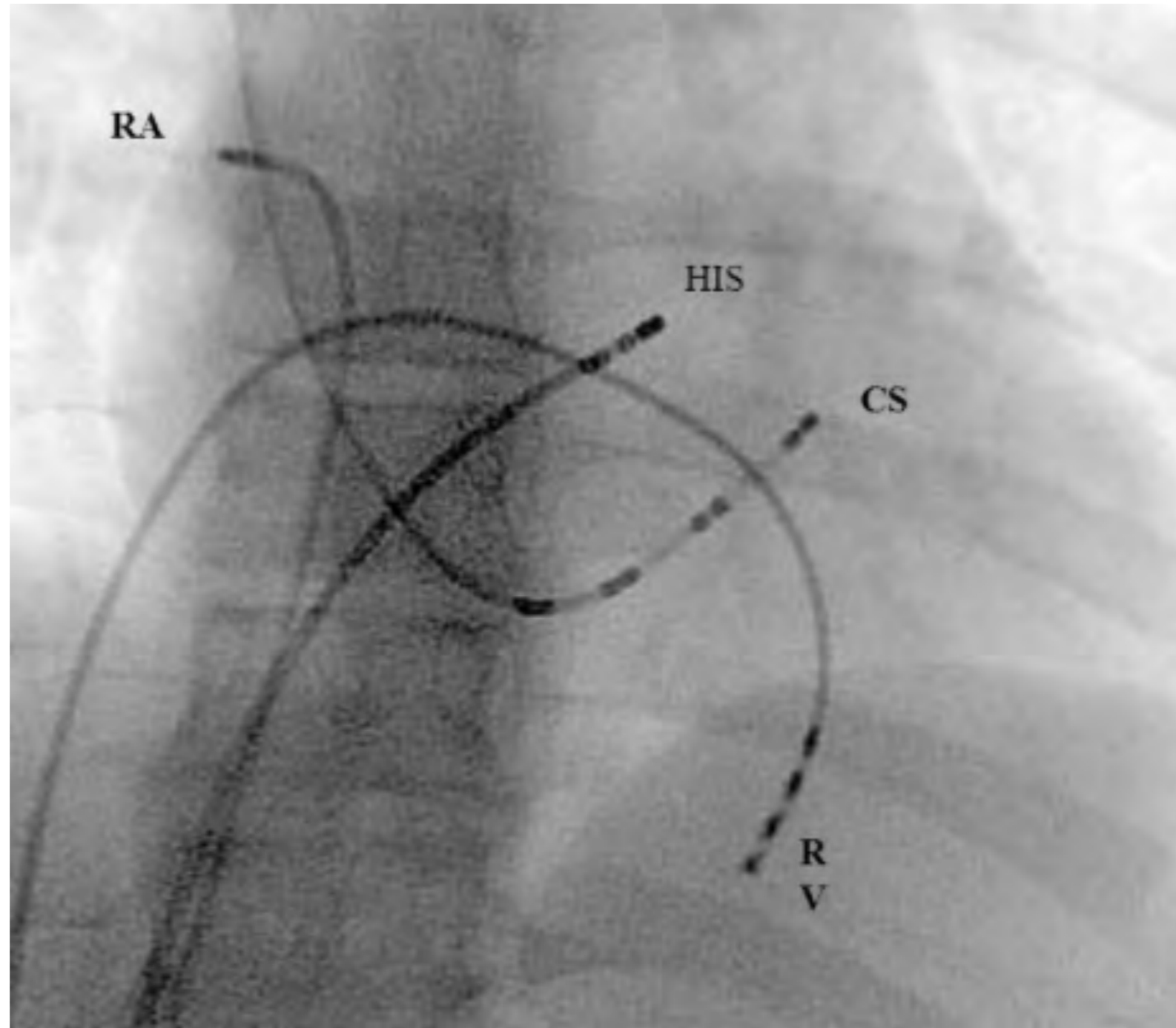






ELECTROCATETER





Interventional Arrhythmology

EHRA 2014 Practical Guide on Radiation Dose Reduction in Electrophysiology

Supplemental Video 2A:

Figure 8

Radiation free construction of LA geometry
using a non-fluoroscopic mapping system

www.escardio.org/EHRA



Interventional Arrhythmology

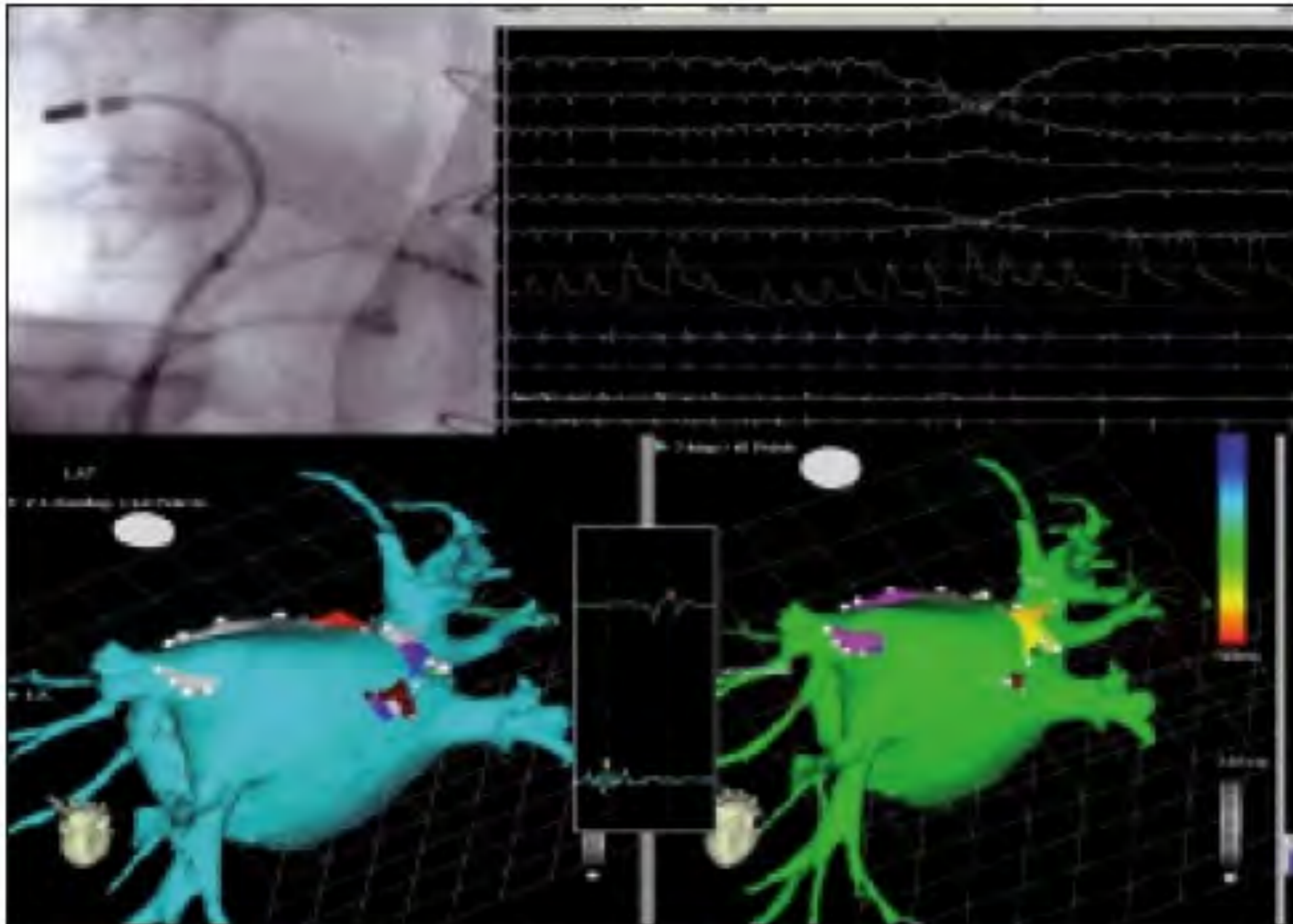
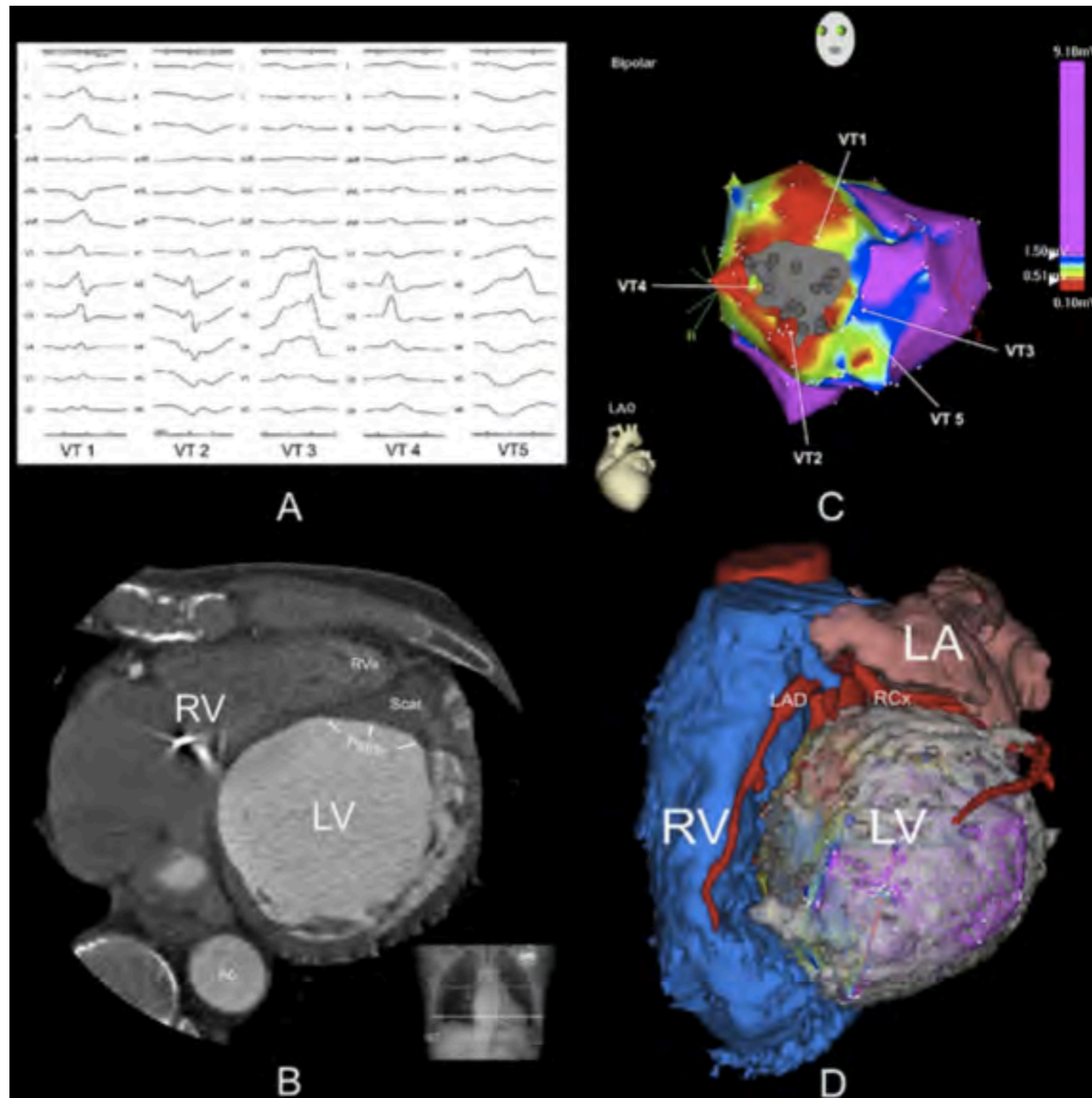


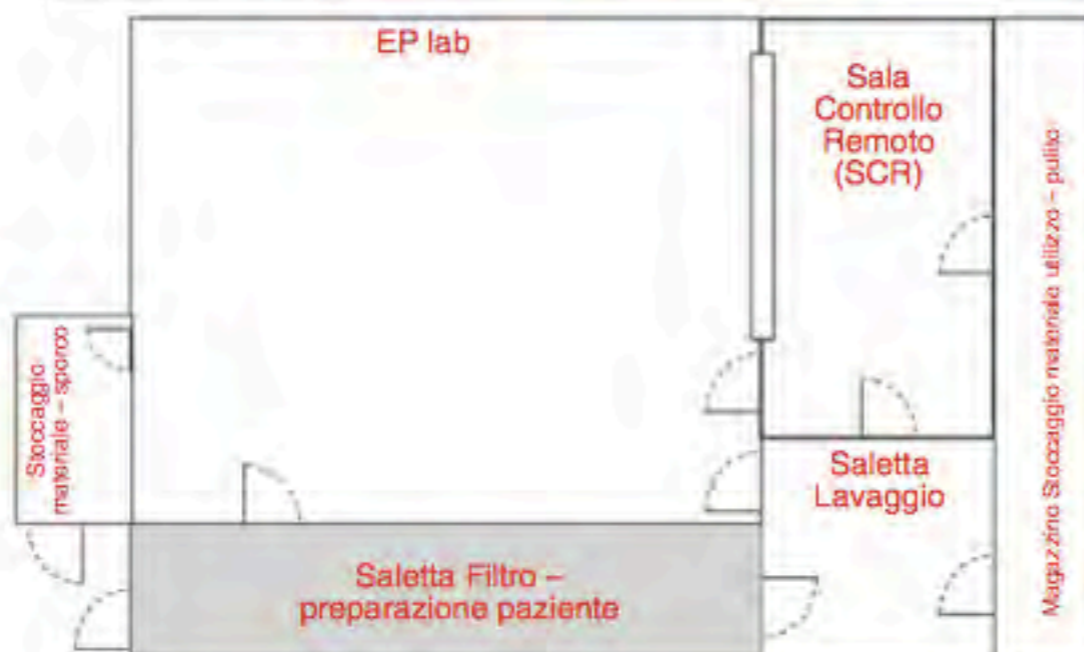
Figura 1. Ablazione di fibrillazione atriale utilizzando la tecnologia CARTOMERGE.

Interventional Arrhythmology



EP Lab (1)

Laboratorio elettrofisiologia Sala impianto PM/ICD (EP lab) – Infrastruttura



► Considerare eventuali delibere assessoriali regionali sui requisiti degli EP lab.

Livello "EP lab standard"

Sala

- 1 EP lab
- 1 Sala Controllo Remoto (SCR)
- 1 Magazzino stoccaggio materiale elettrofisiologia/device – Area Pulito
- 1 Area sporco
- 1 Saletta Lavaggio
- 1 Sala Filtro – Area preparazione pz

Dimensioni

- EP lab + sala controllo remoto: 35 m²
- Altezza pareti: minimo 2 m

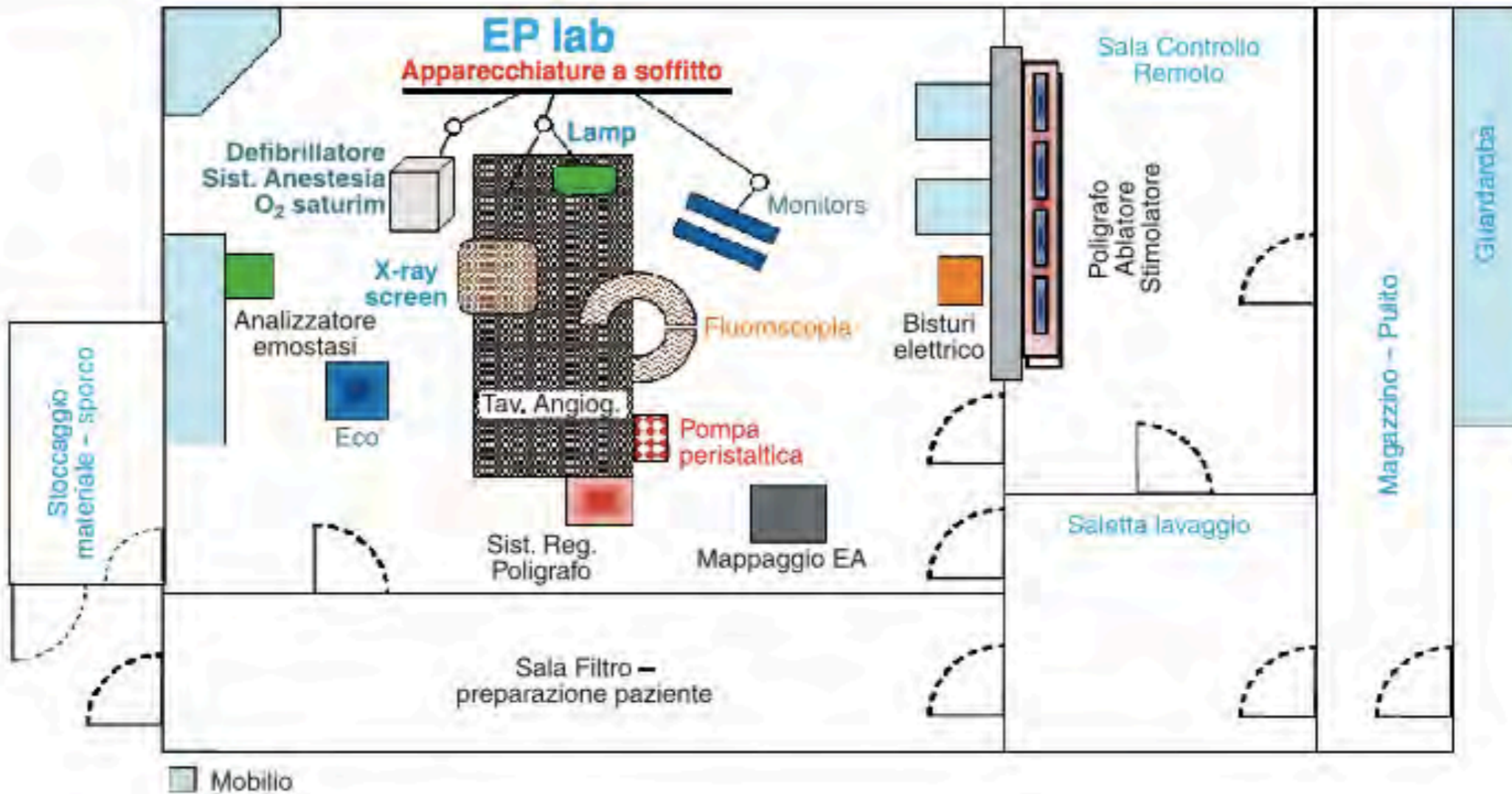
Requisiti tecnici

- Muri e Porte piombate
- Gabbia di Faraday

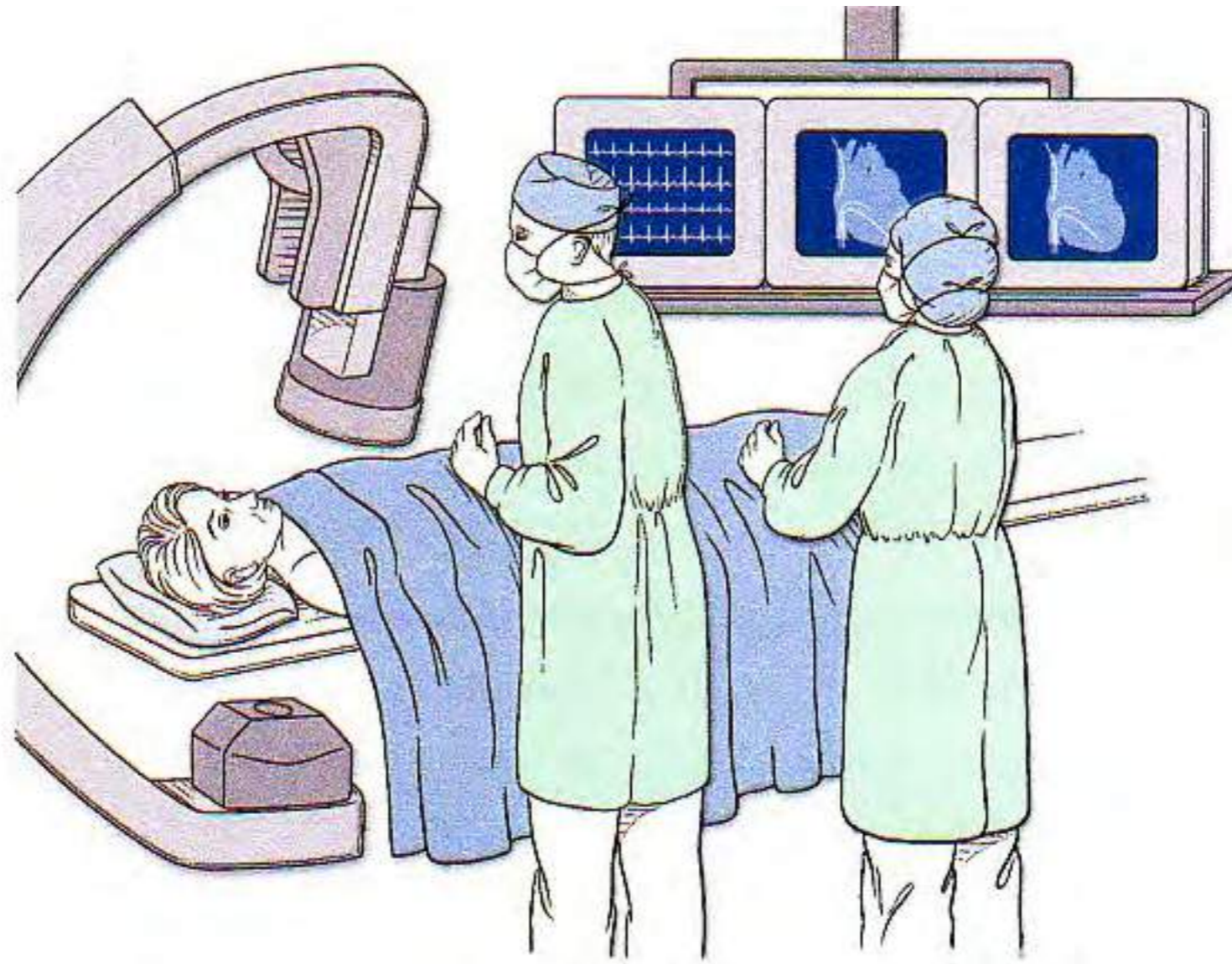
Livello "EP lab di Eccellenza"

- Preparazione per la Stereotaxis (considerare spazio addizionale o 2^a sala; muri schermati)
- 2^a sala per impianto PM/ICD

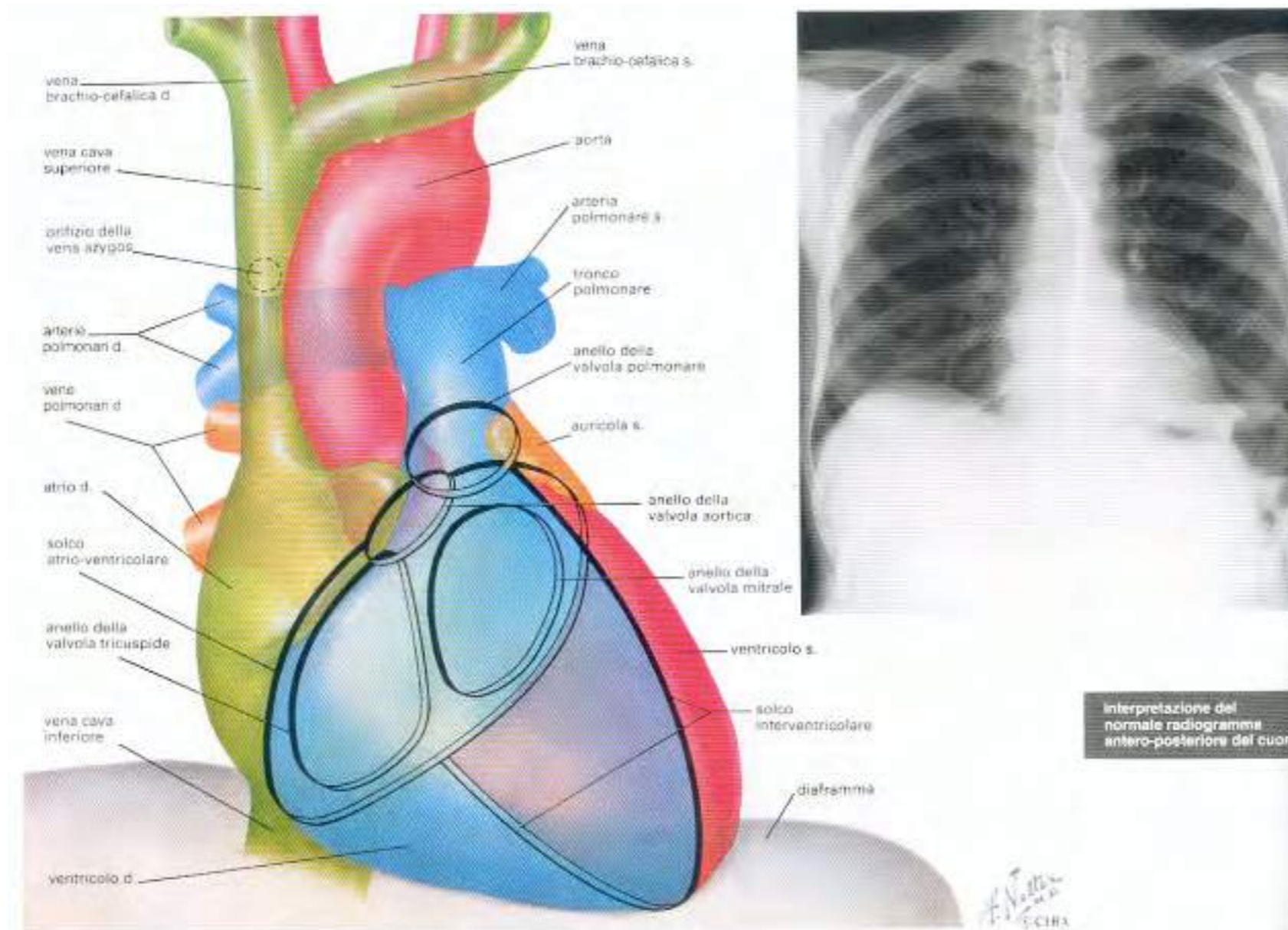
EP Lab (2)



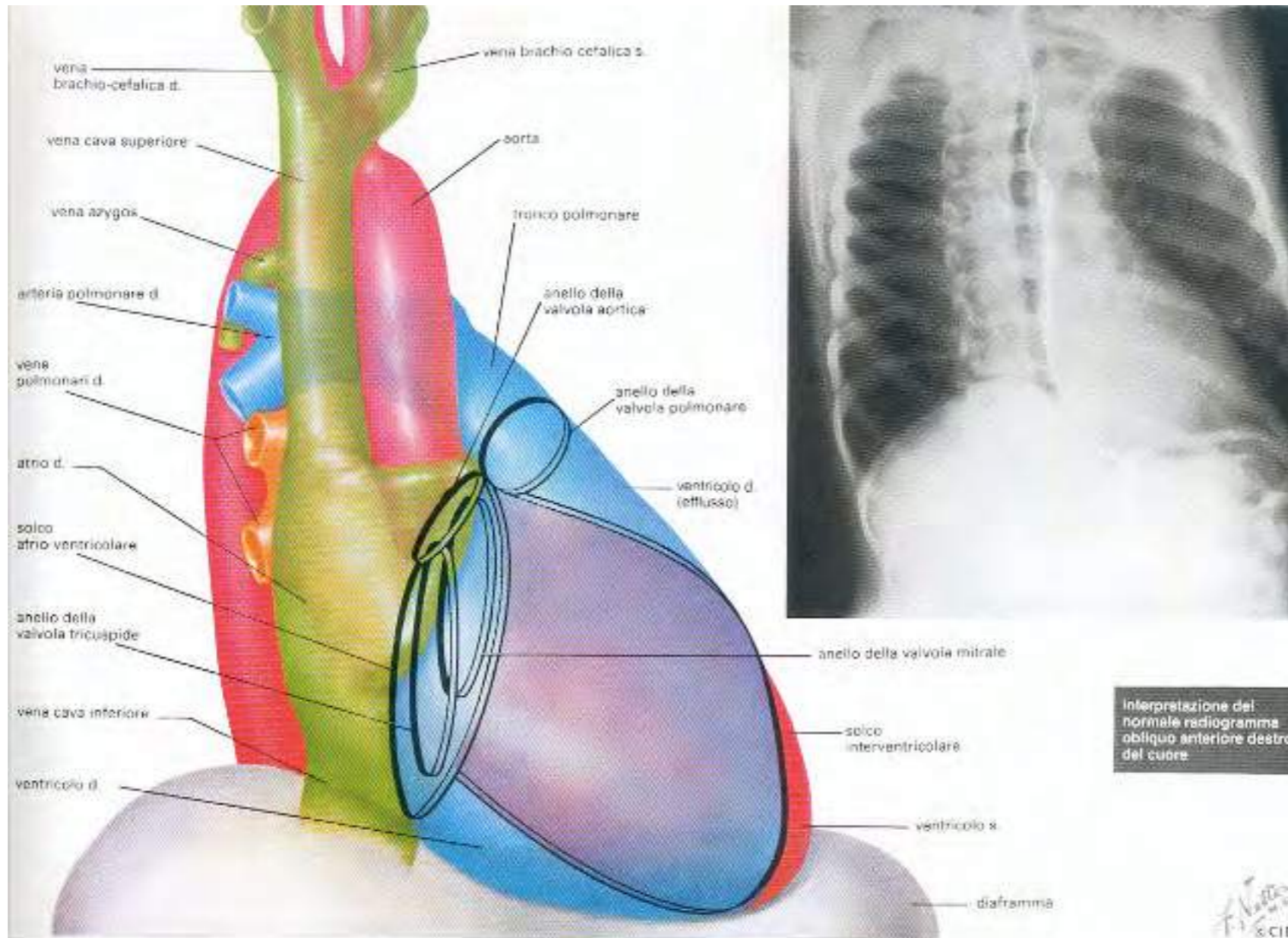
In EP Lab...



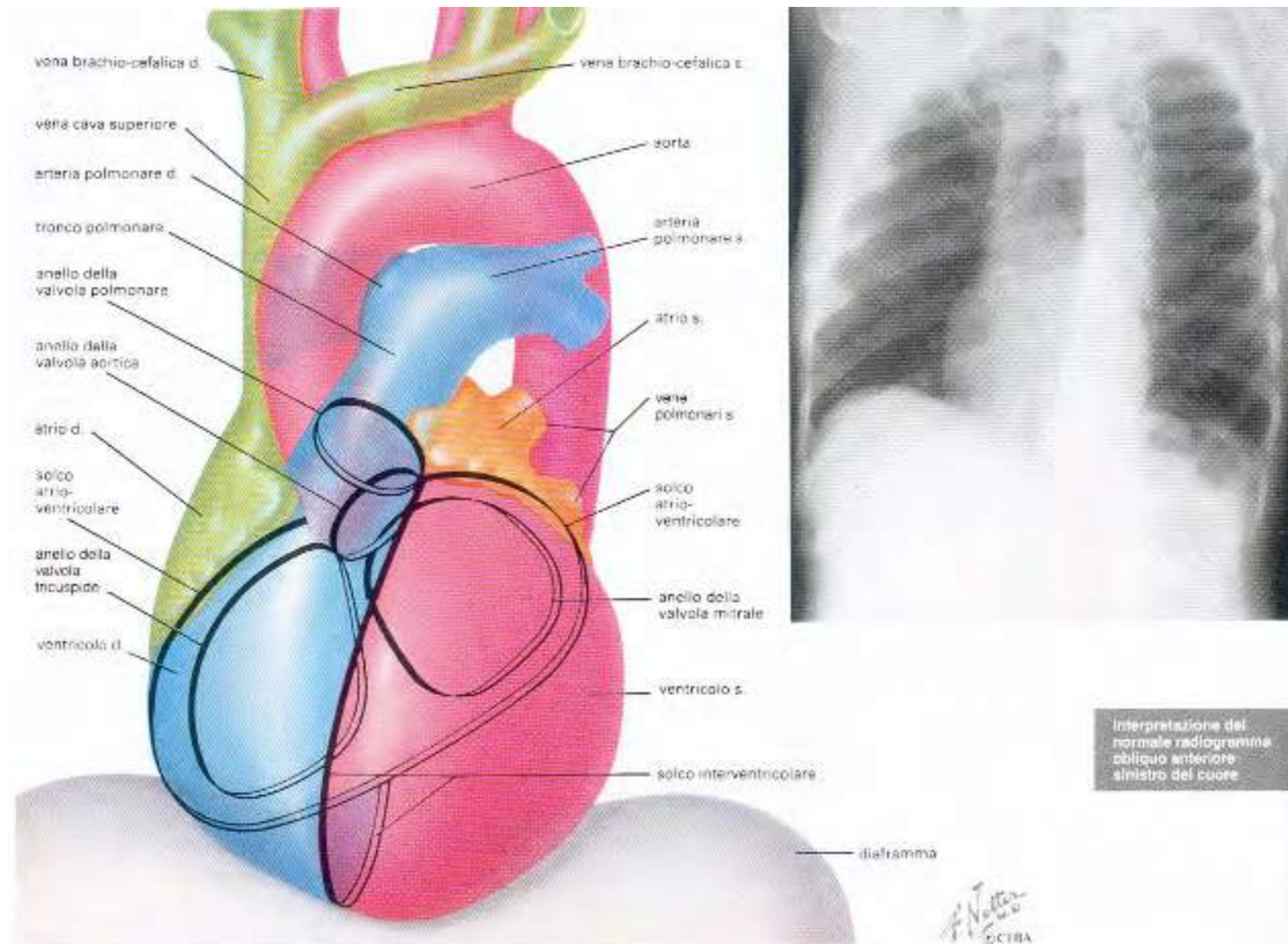
AP



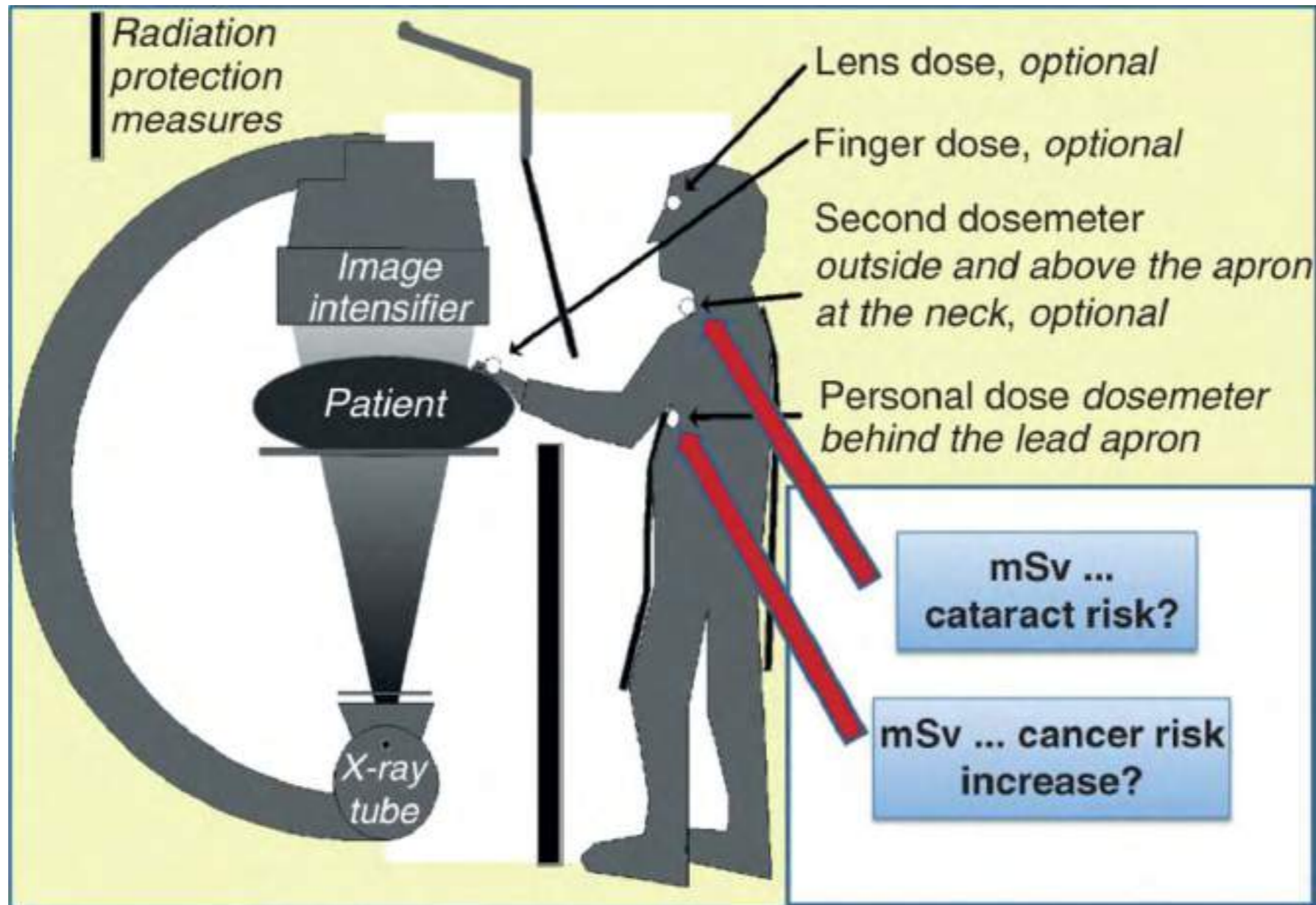
RAO



LAO



Recommended use of at least two dosimeters, one above and one underneath the lead apron.



Shielding measures during EP procedures.


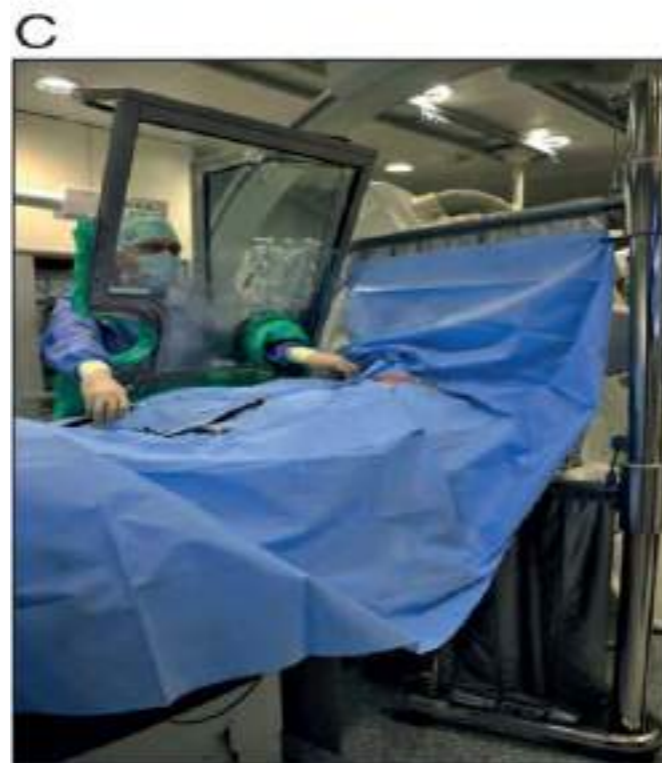

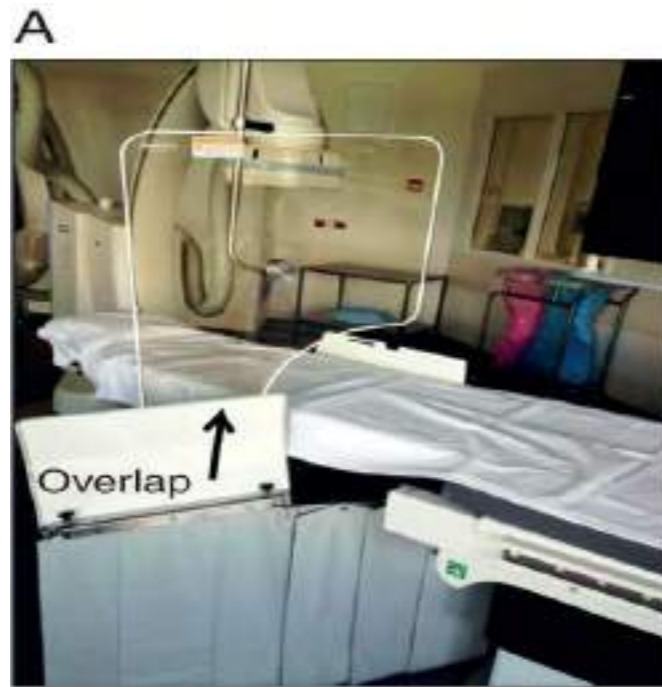



Figure 6 Fluoroscopic imaging with lower dose settings often suffices for EP applications (right PV isolation).



Interventional Arrhythmology

procedures	n.	
	2017	2019
PM implantation	282	285
ICD implantation	48	58
CRT	17	23
Ablation with NAVEX	23	1
Ablation with CARTO	64	101
Mapping	0	3
SEF	13	23
EPS+CARTO	5	5
Ablation with radiation exposure	14	21
Totale	466	520

Interventional Arrhythmology

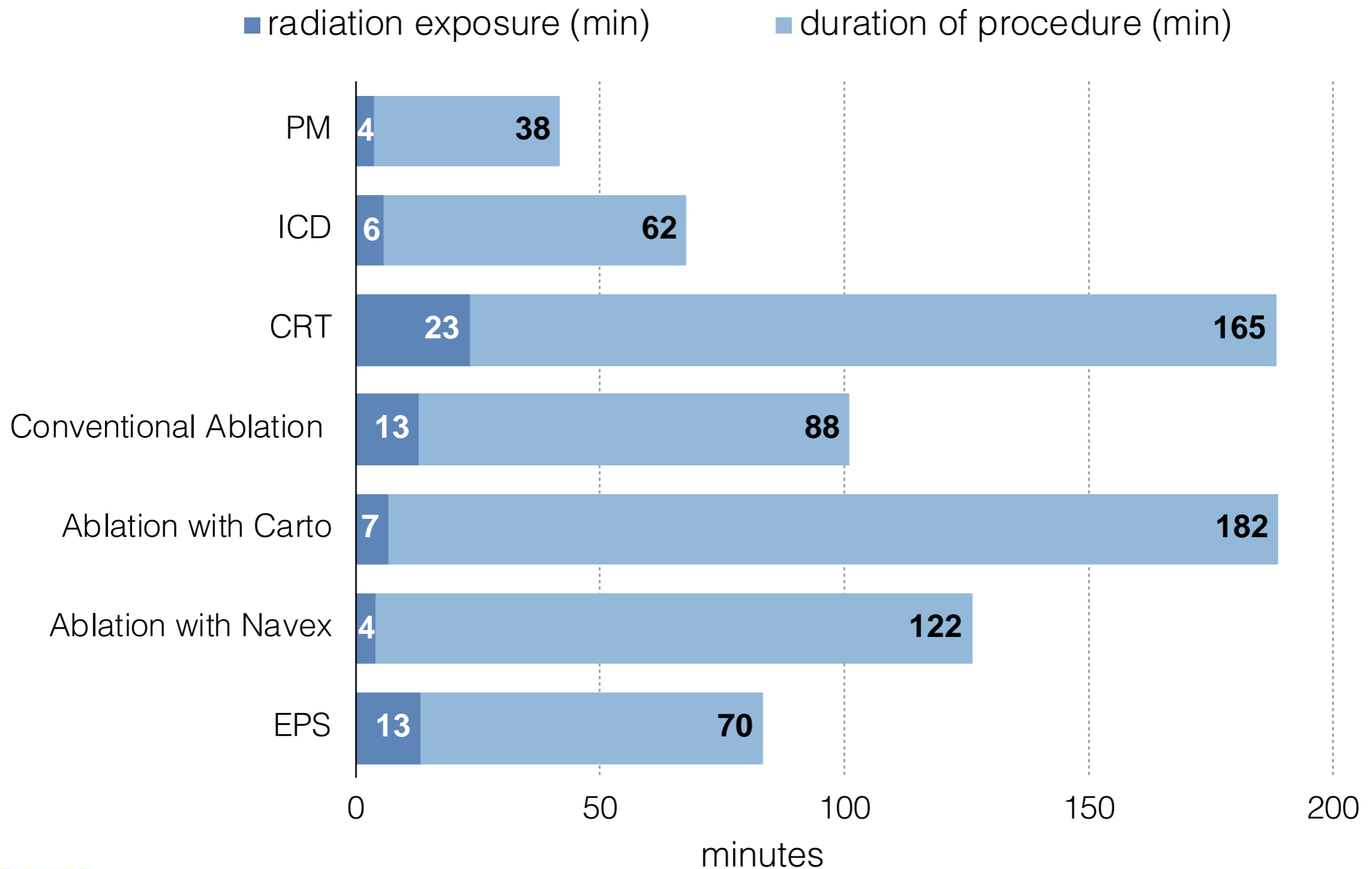


Table 3

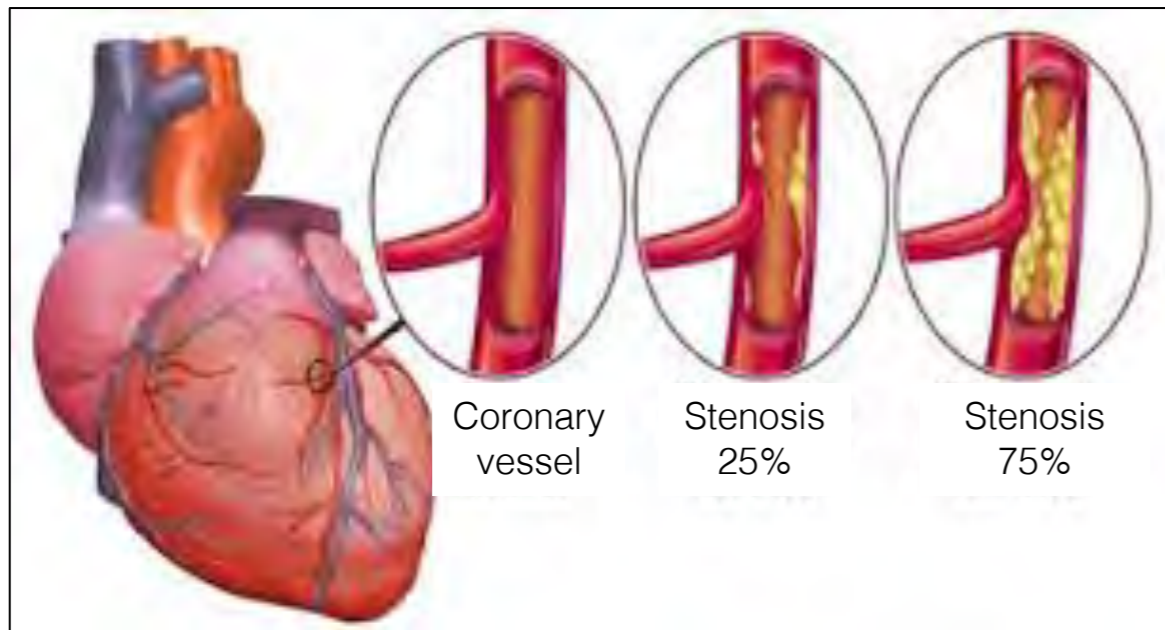
Typical patient radiation doses for common EP procedures

Type of study	Dose to patient mSv median and range
Diagnostic EP study	3.2 1.3–23.9
Ablation procedure	15.2 1.6–59.6
AF	16.6 6.6–59.6
AT – AVNRT – AVRT	4.4 1.6–25
VT	12.5 3–≥45
VVI/DDD PM or ICD implant	4 1.4–17
CRT implant	22 2.2–95
Coronary angiography	7 2.0–16
Percutaneous coronary intervention	15 7–57

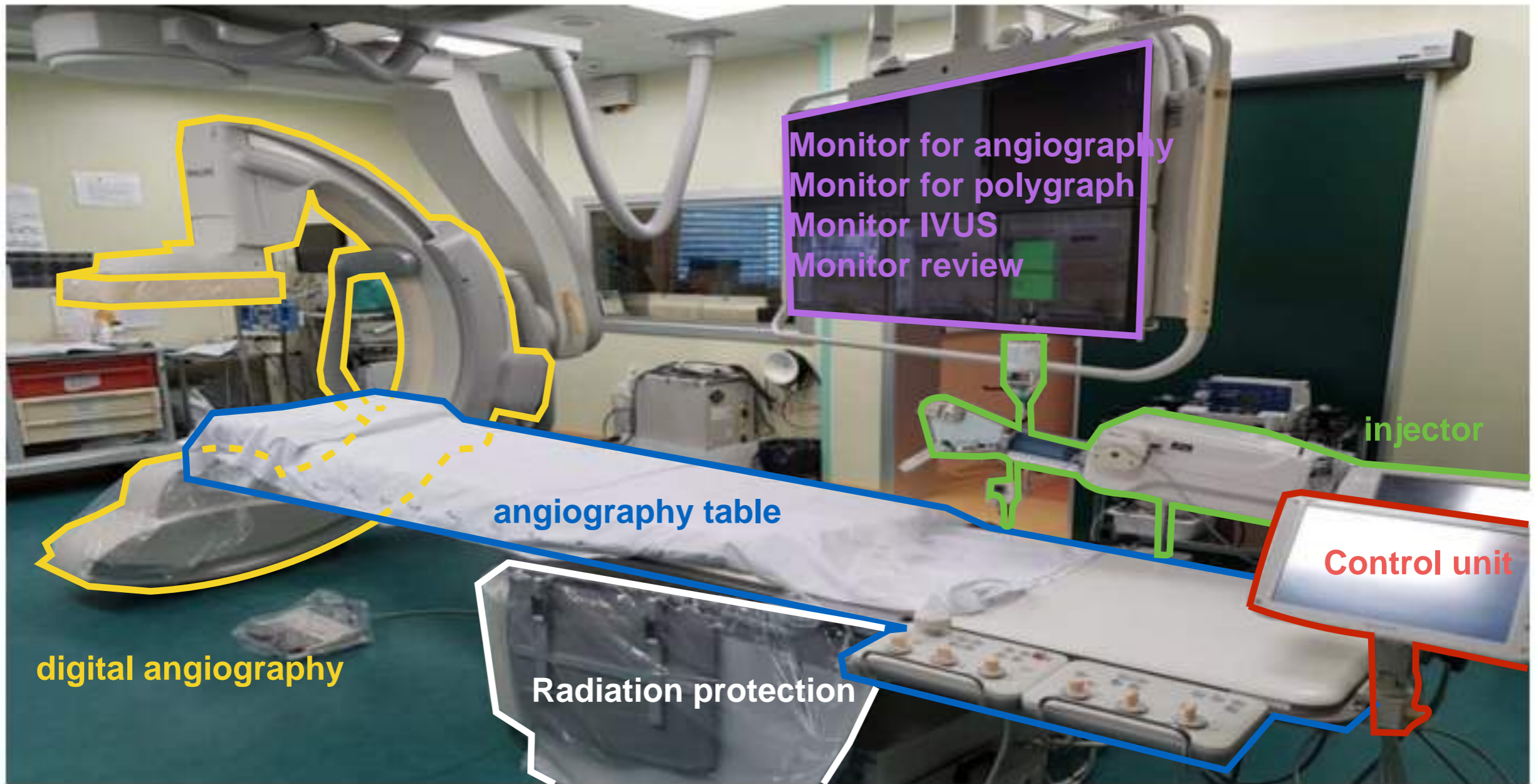
Cath Lab



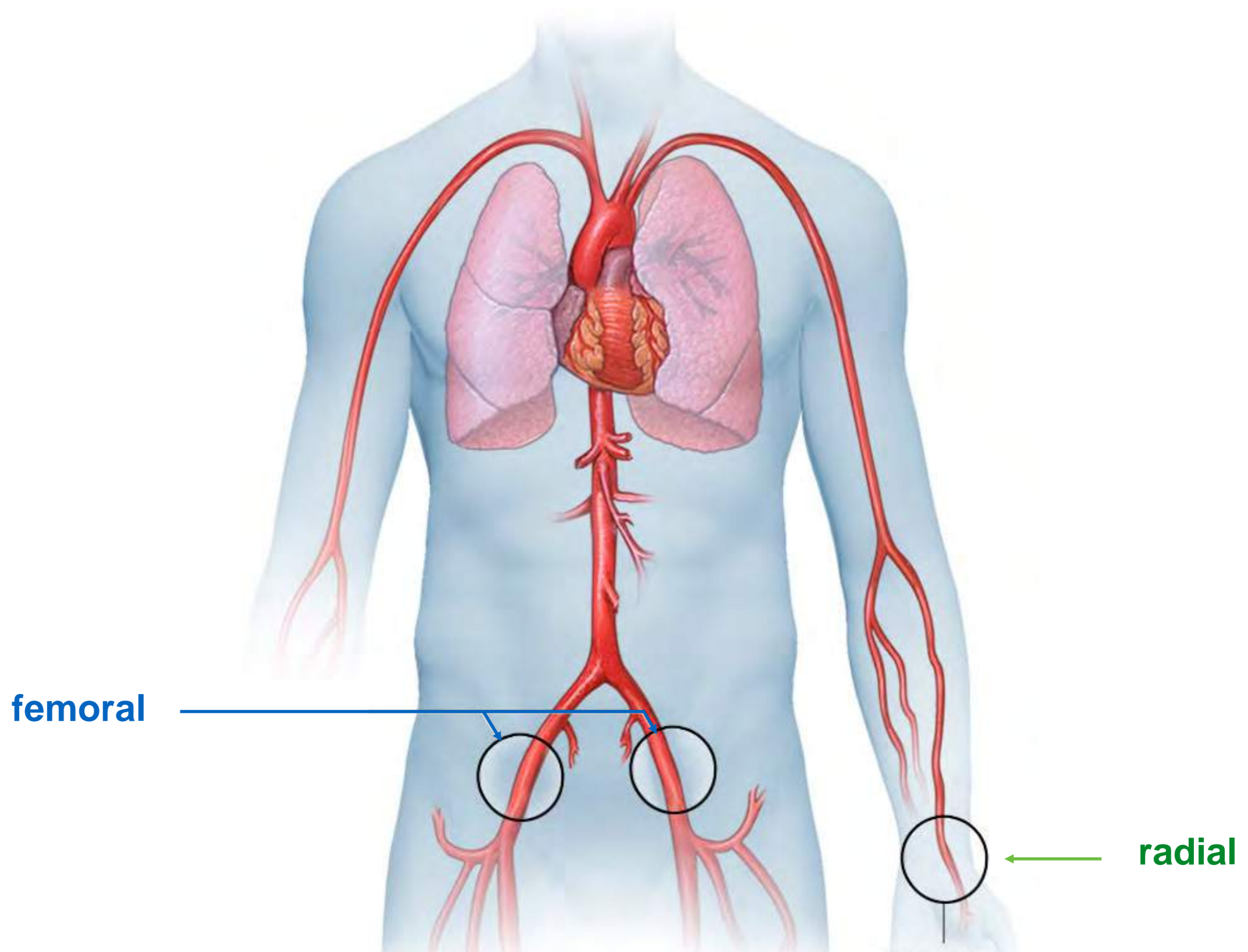
Coronarography



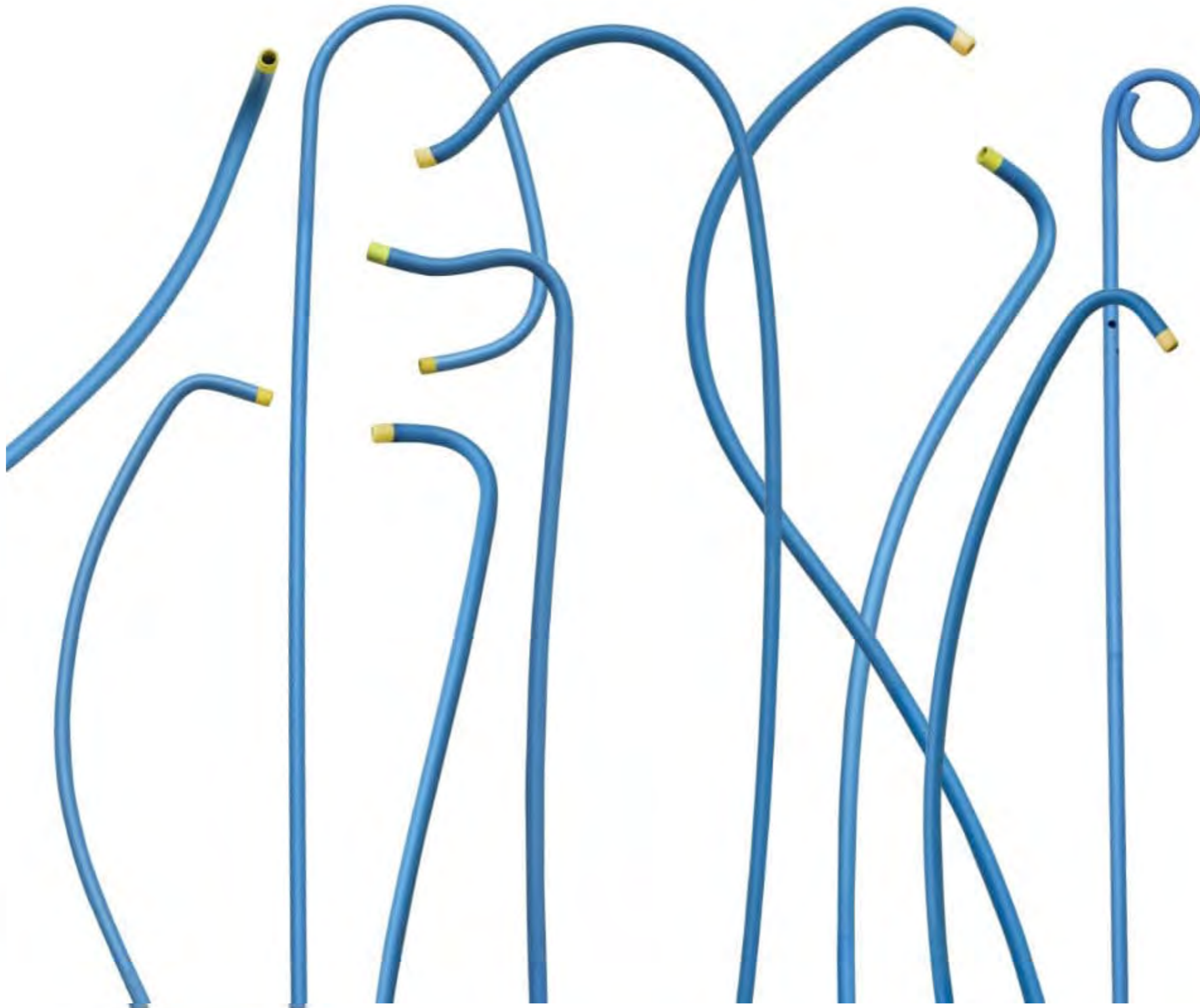
Cath Lab



Transvenous access for coronarography

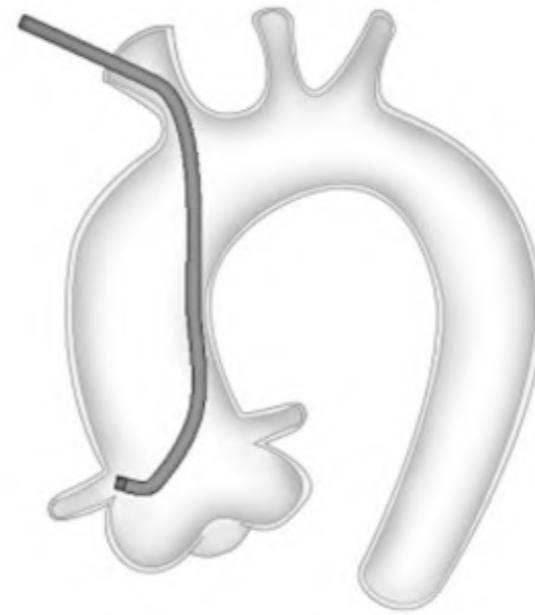


Catheters for coronarography

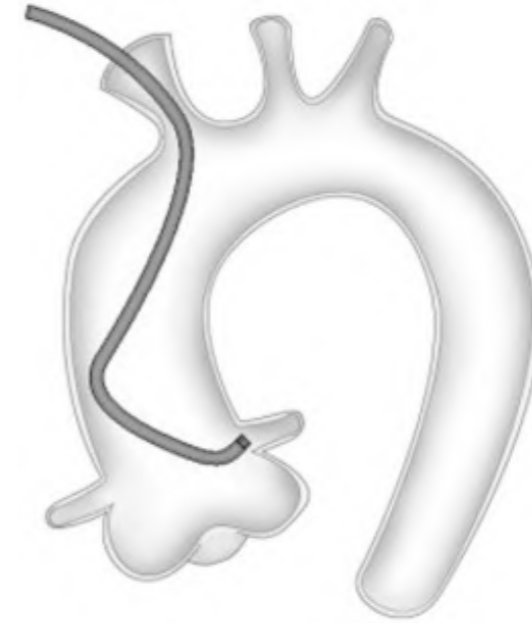


Catheters for coronarography

Radial access

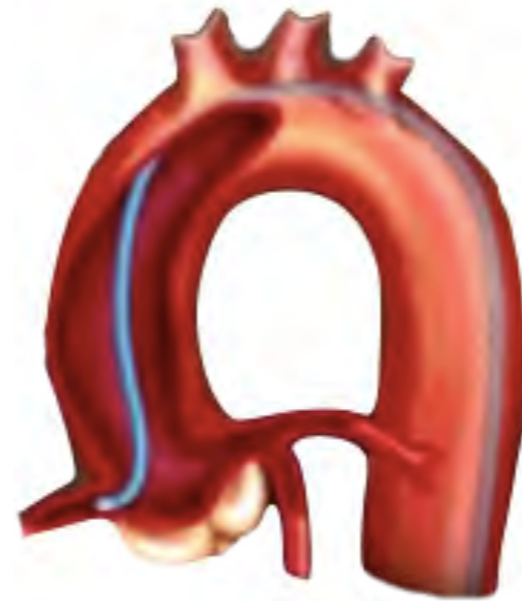

Right coronary artery

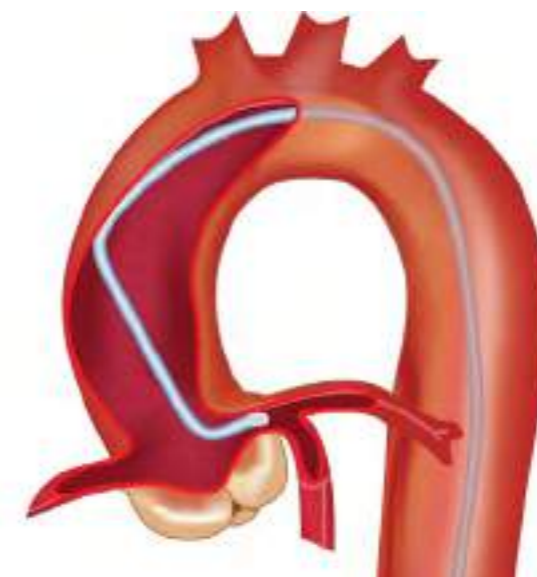


Left coronary artery

Femoral access

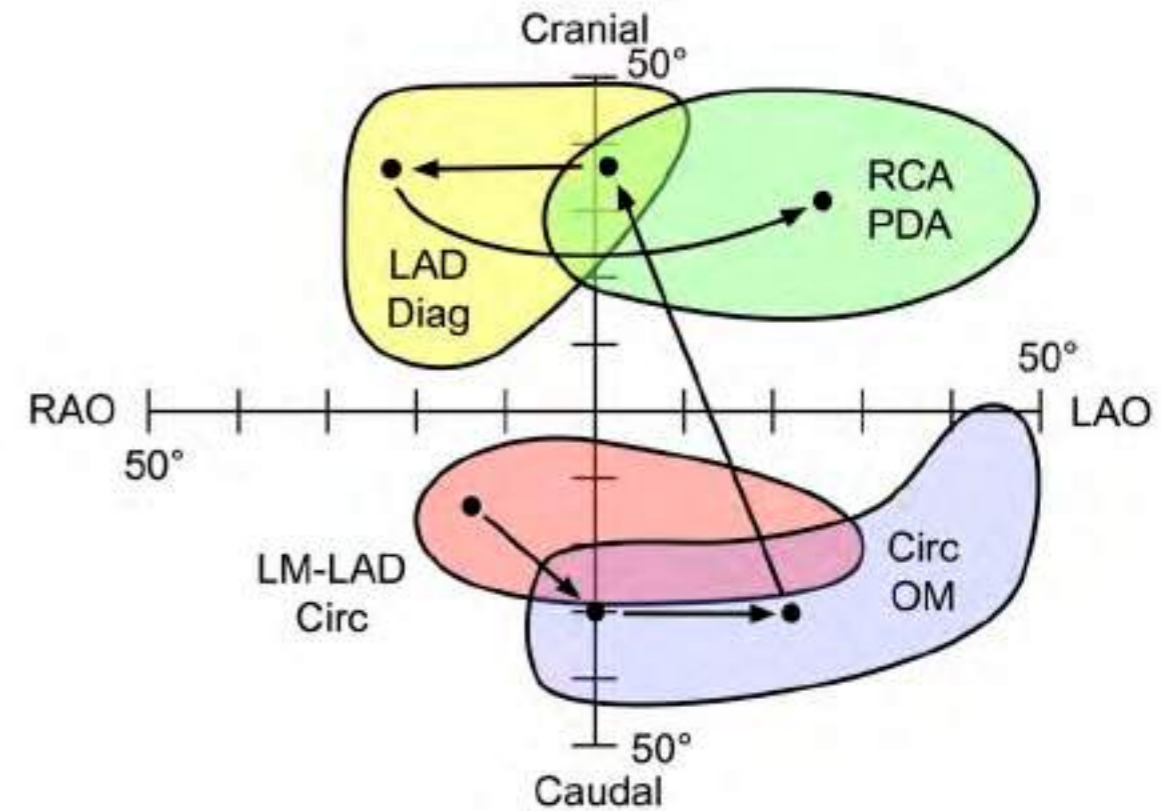
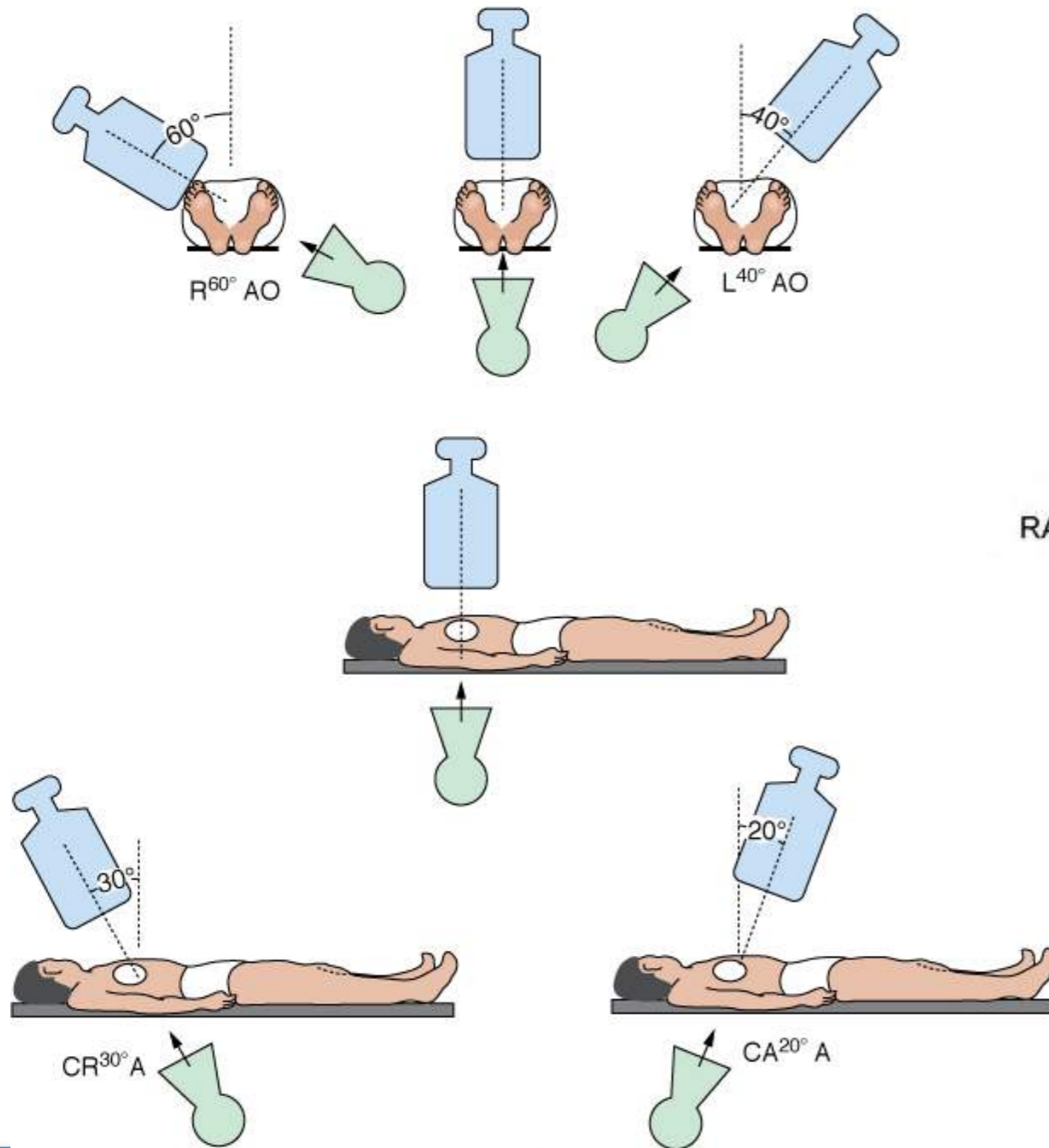


Right coronary artery

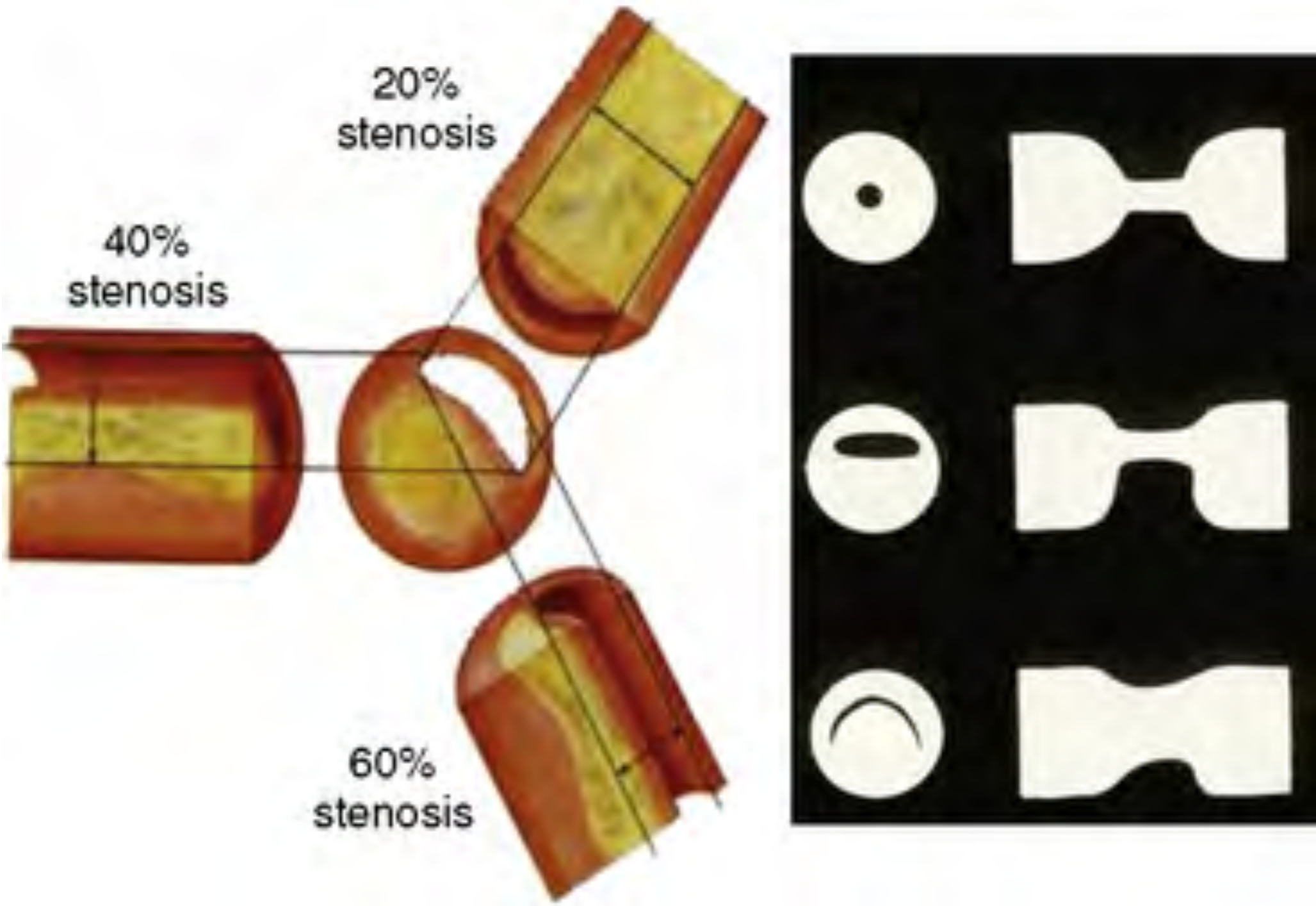


Left coronary artery

Angiographic Projections

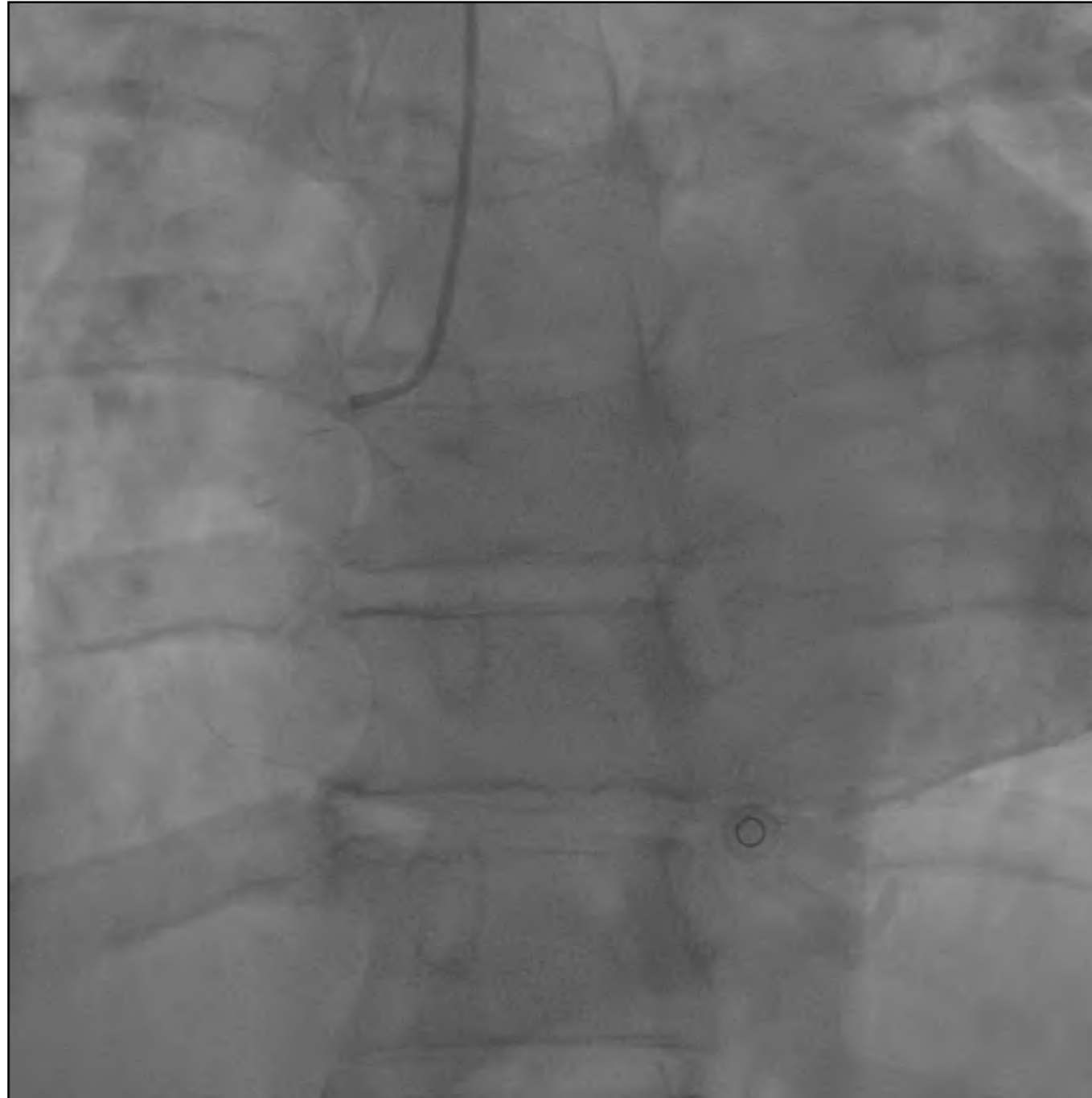
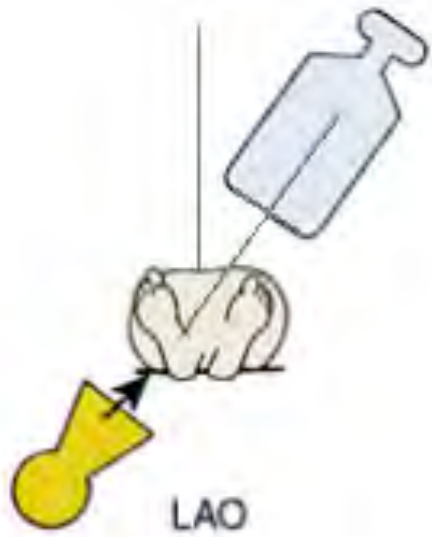

Angiographic Projections

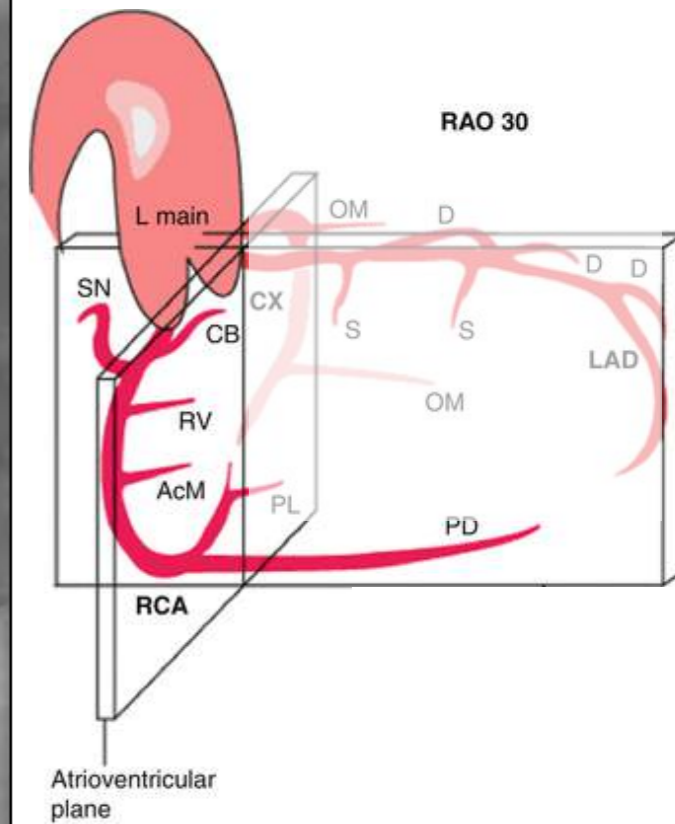


Coronarography

Right coronary artery

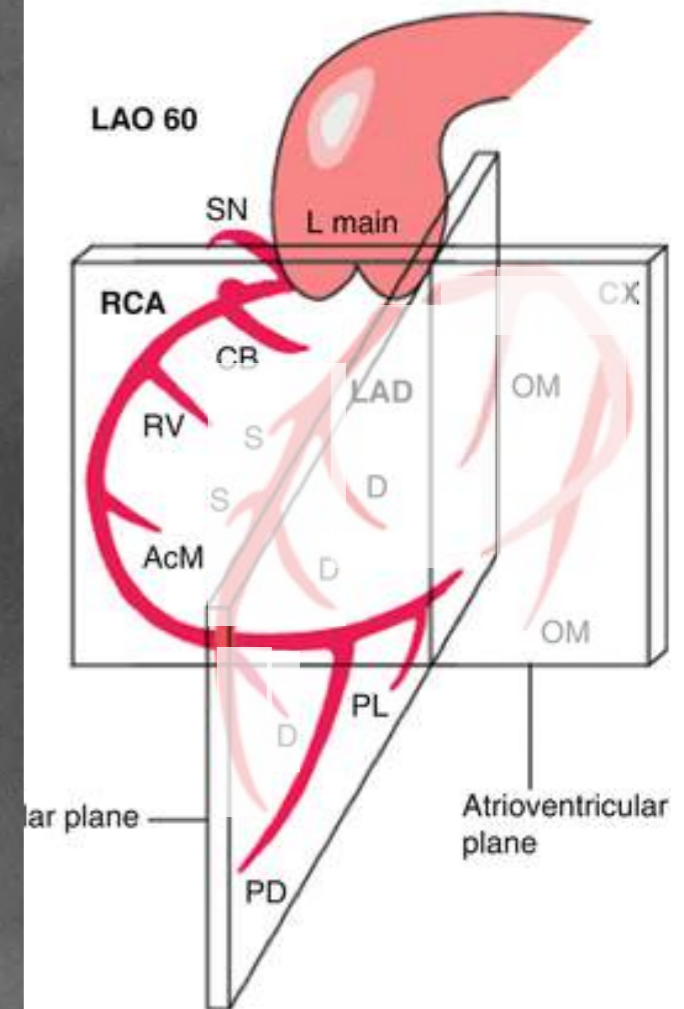
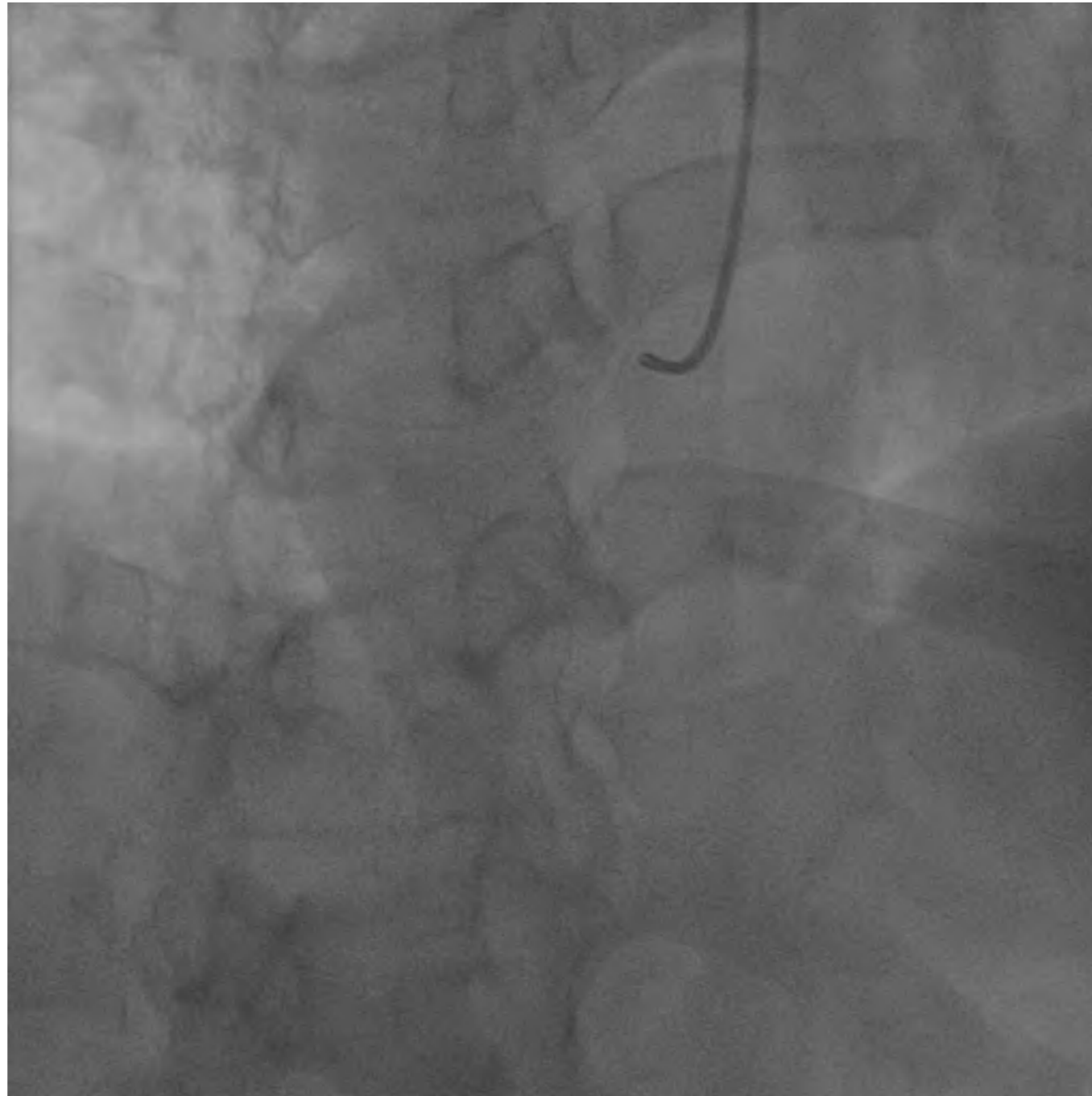
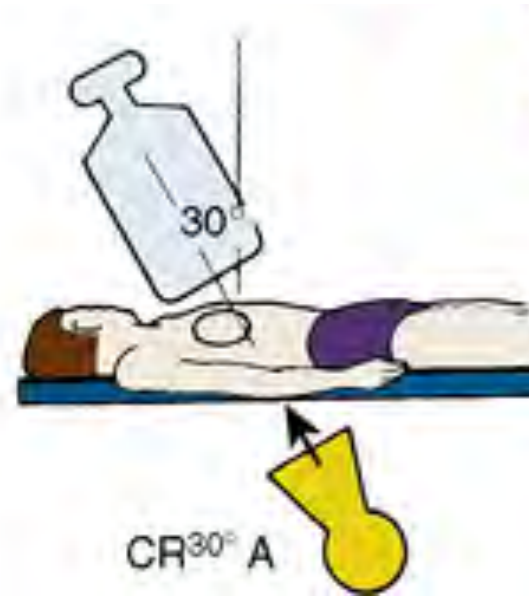

LAO 30°



Coronarography

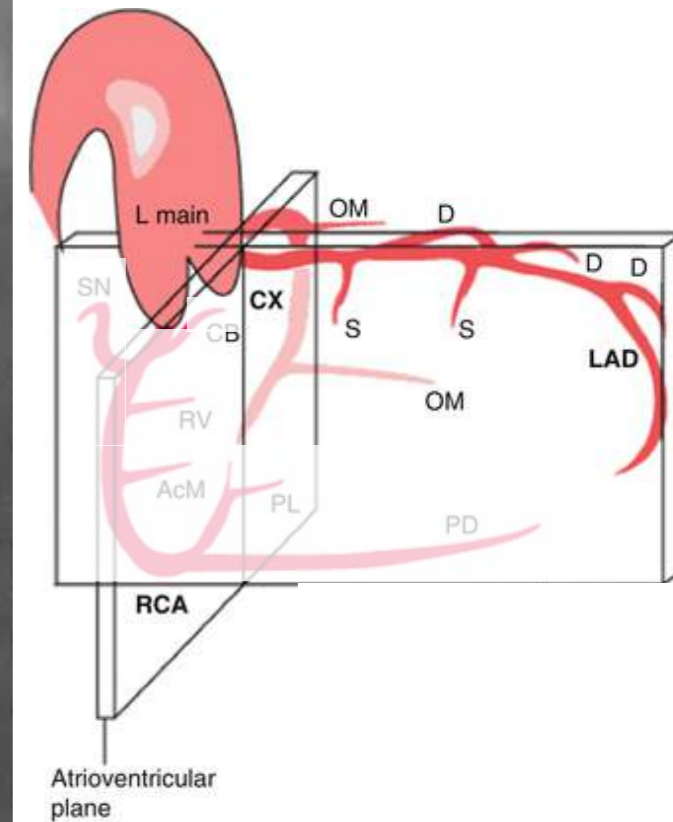
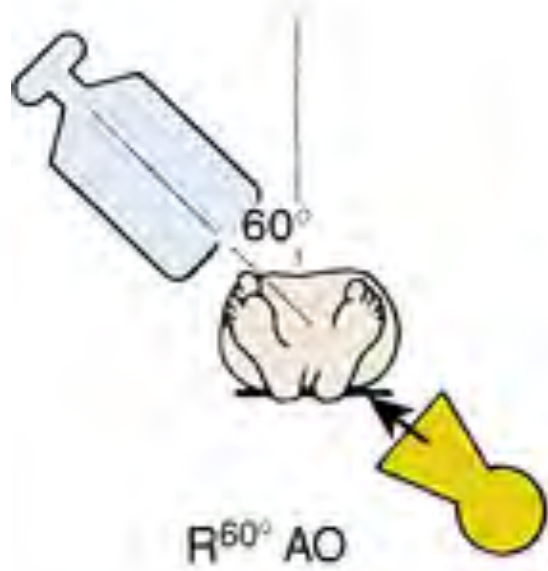
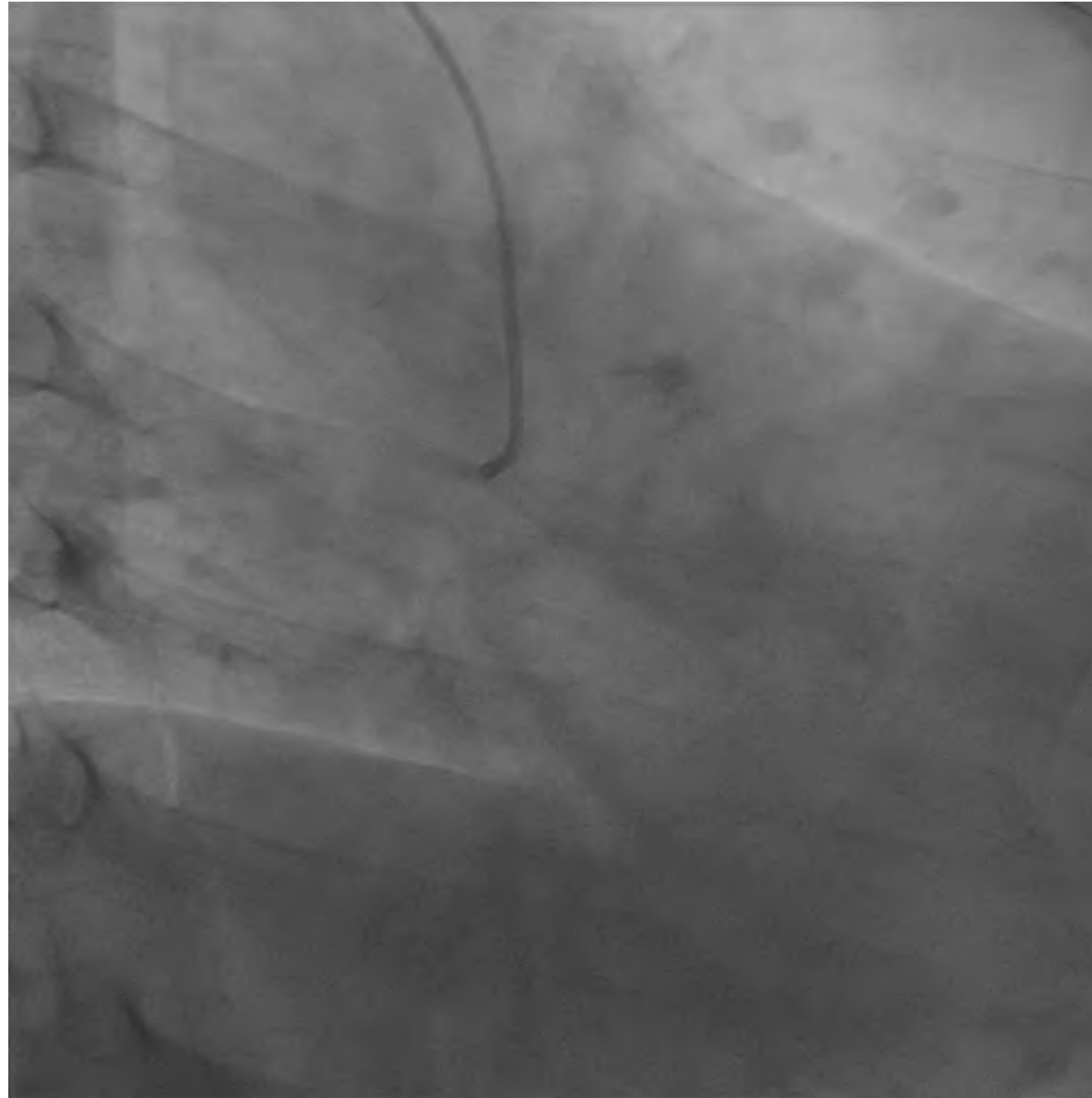
Right coronary artery



CRA 30°

Coronarography

Left coronary artery

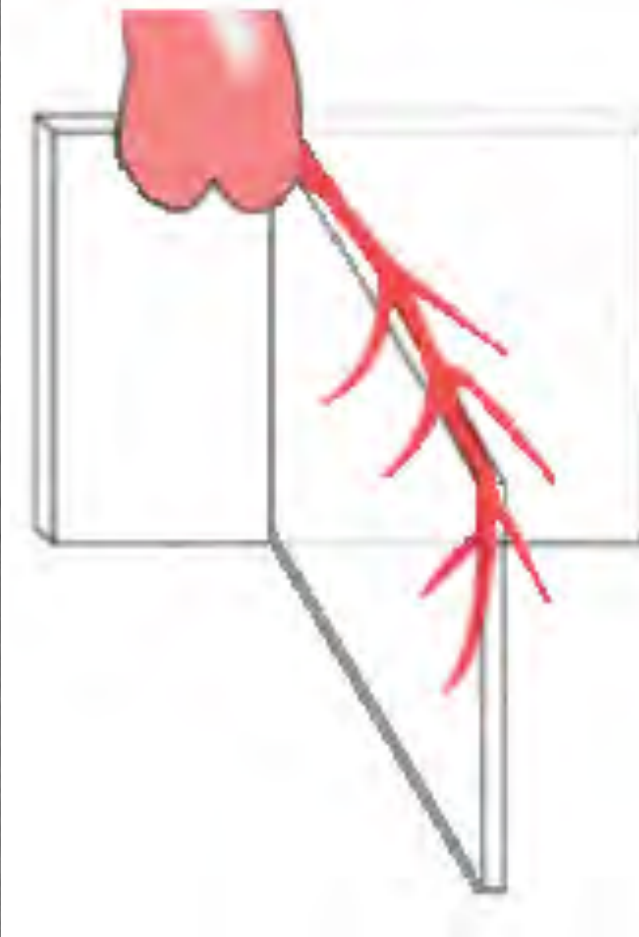
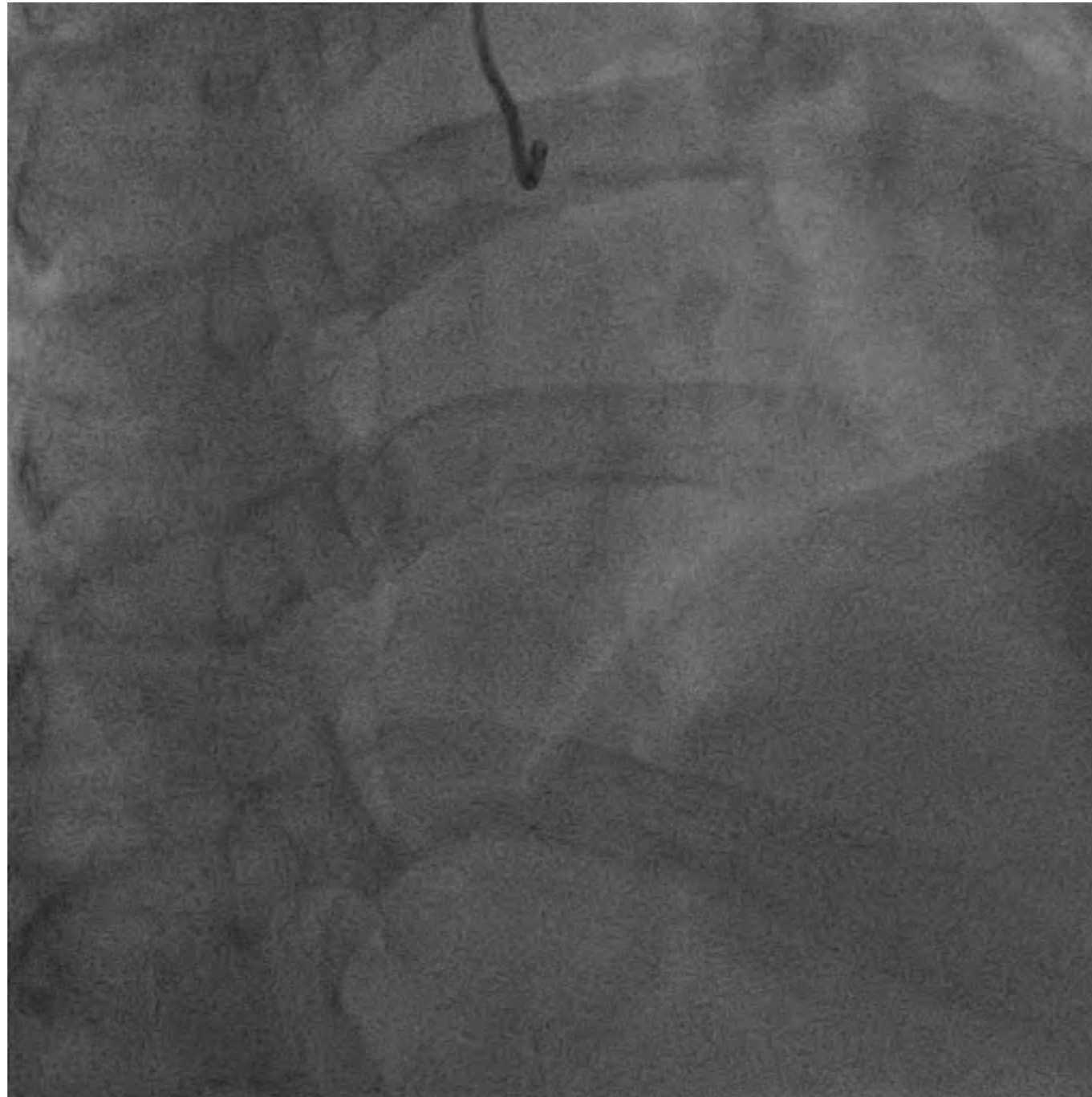
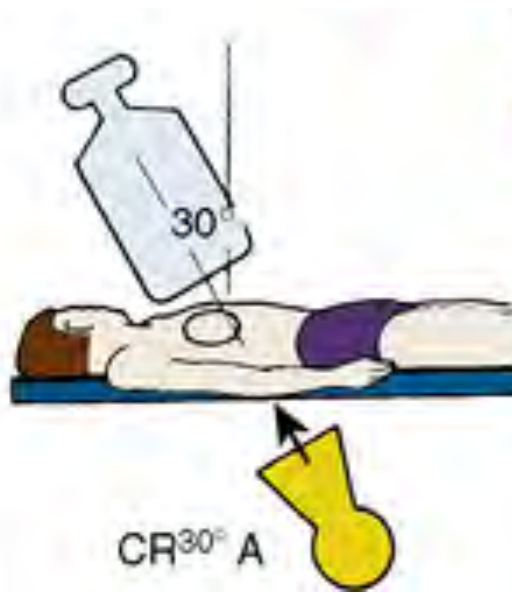

RAO 30° CAU 10°

Standard projection for Cx

Coronarography

Left coronary artery

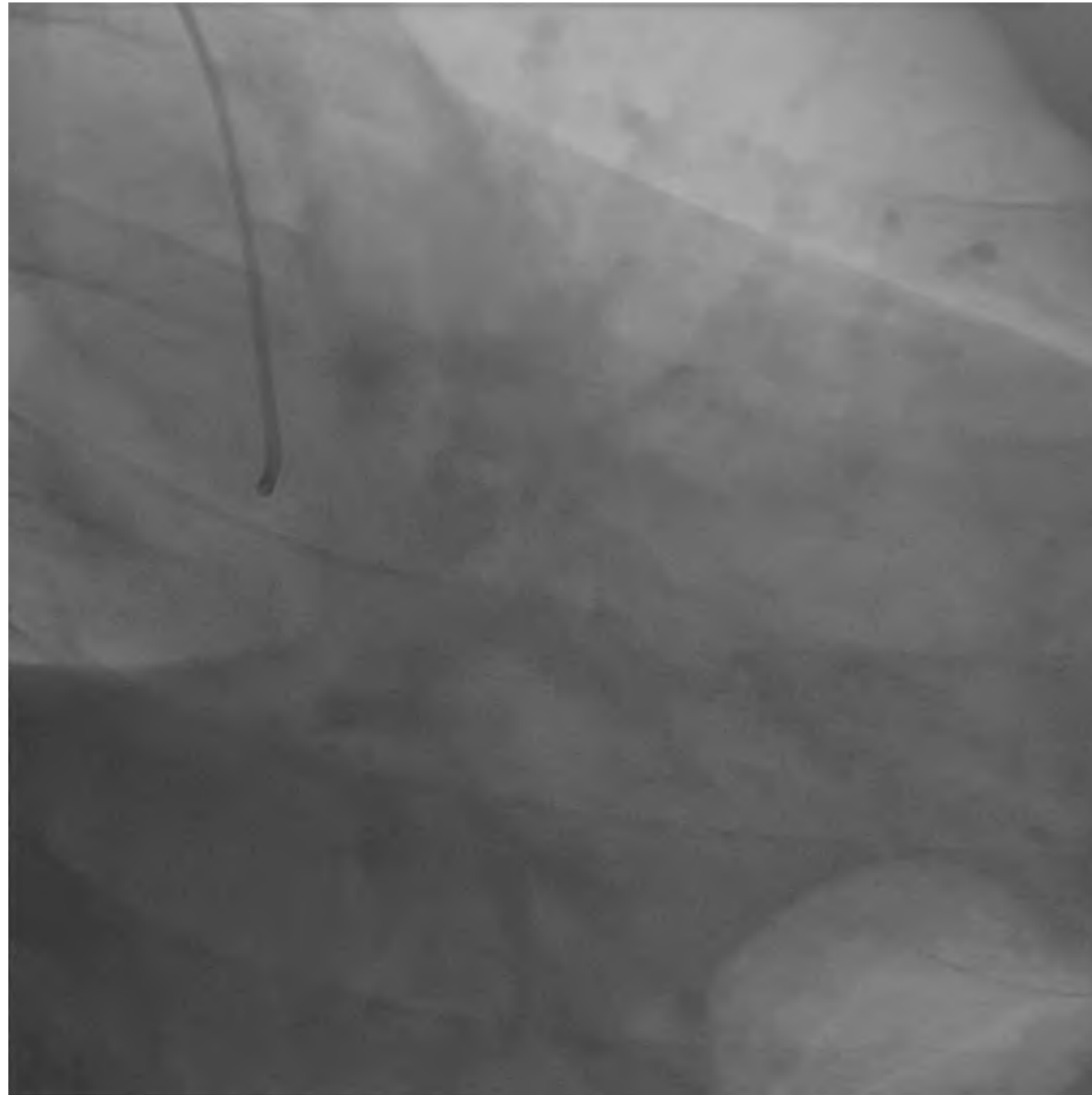


CRA 30°

Standard projection for IVA

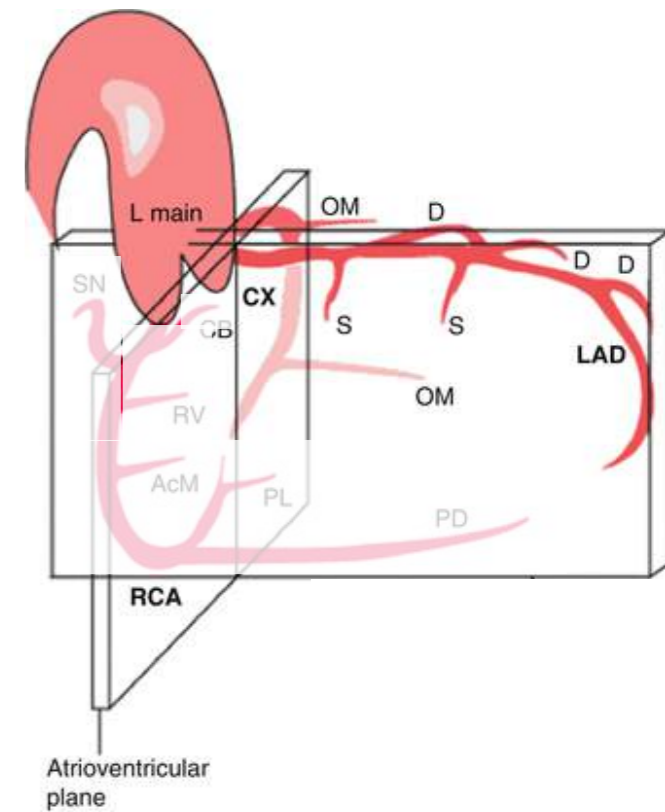
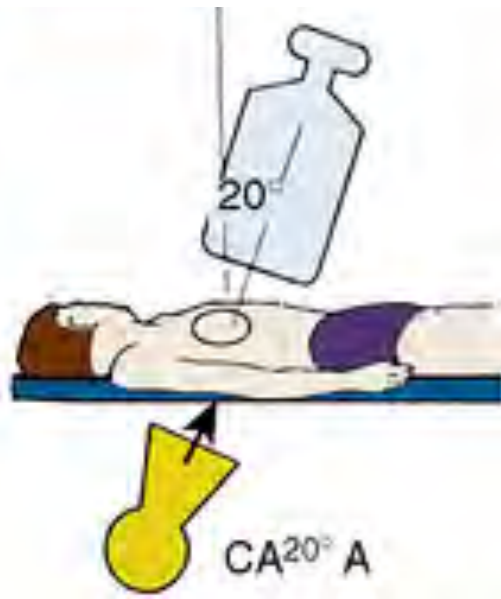Coronarography

Left coronary artery



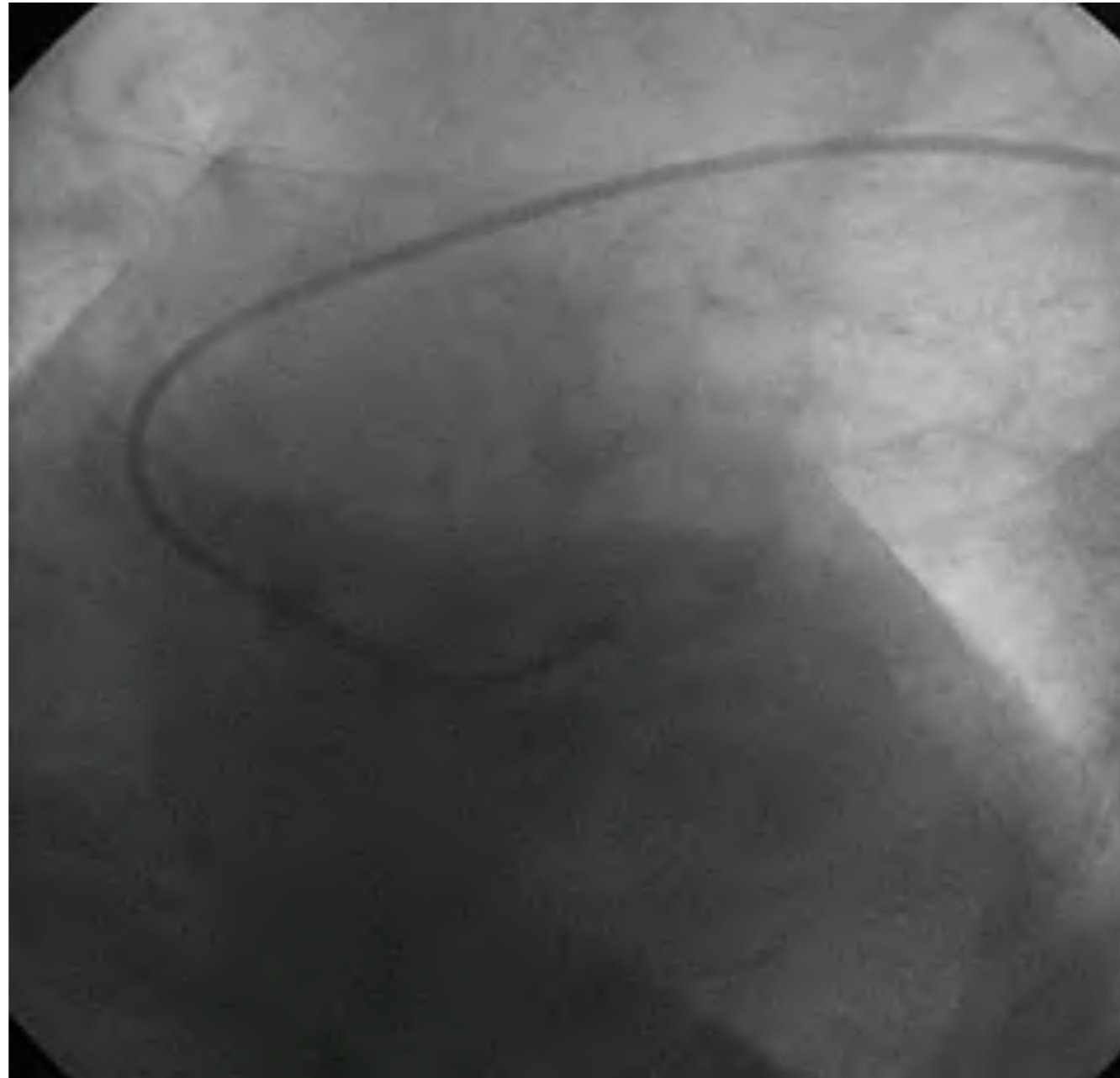
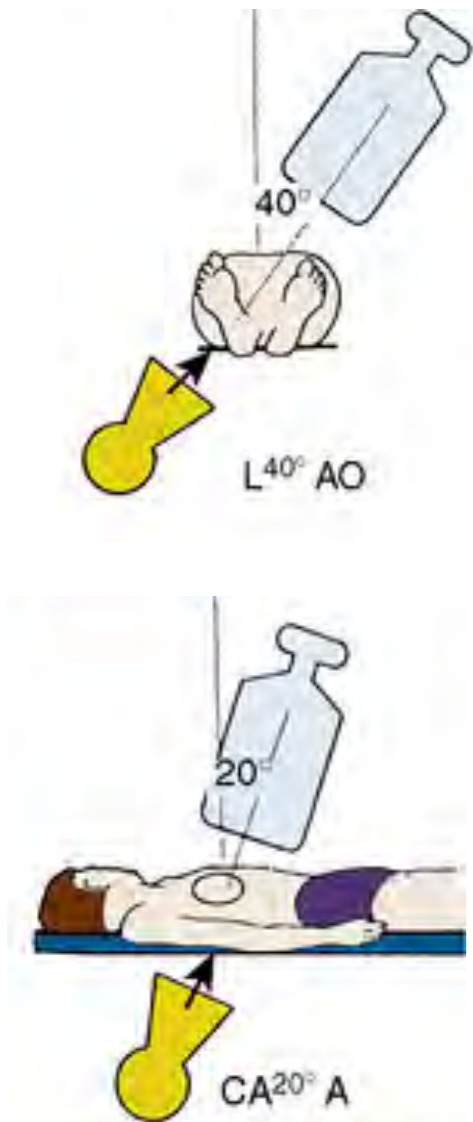
CAU 30°

CX-IVA



Coronarography

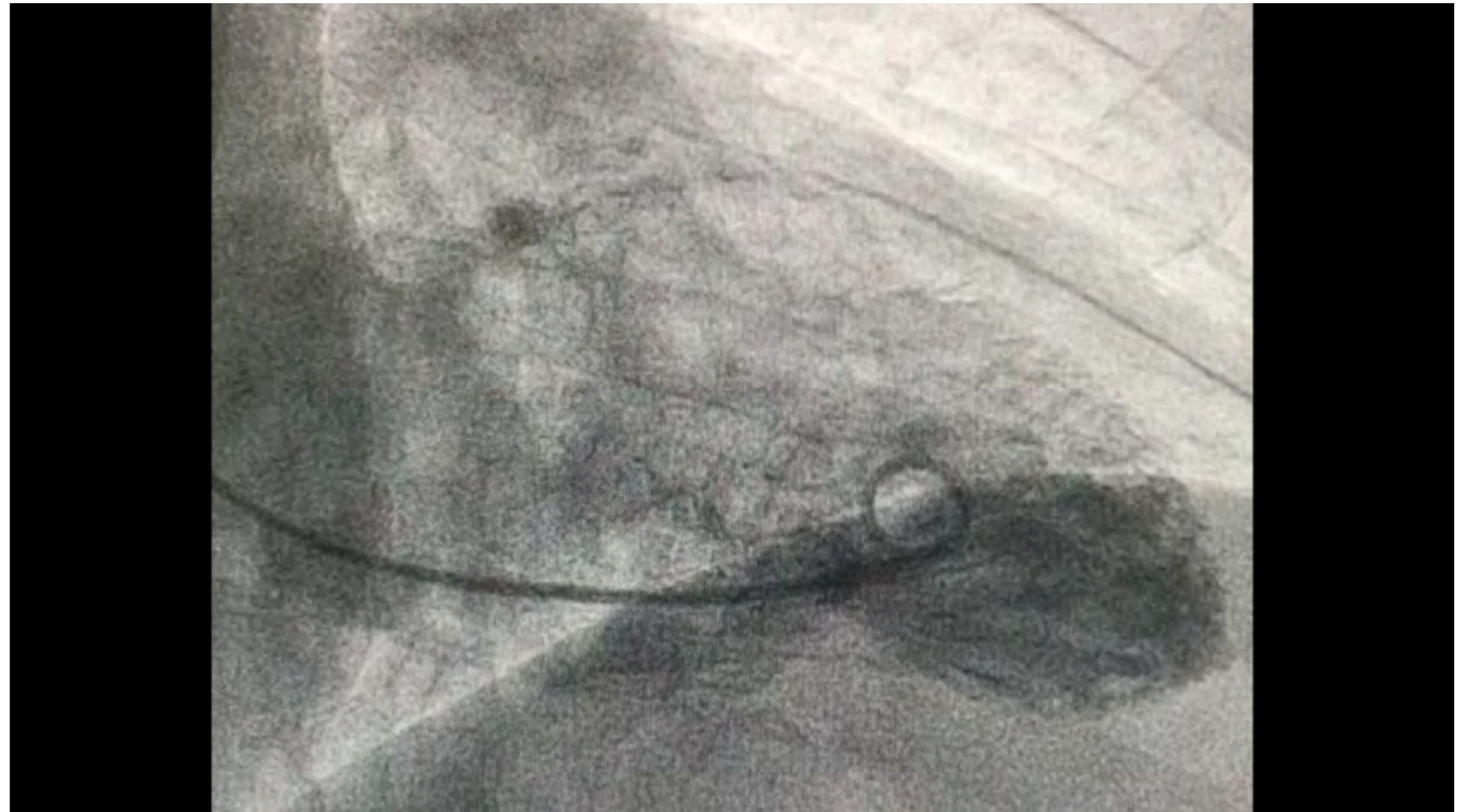
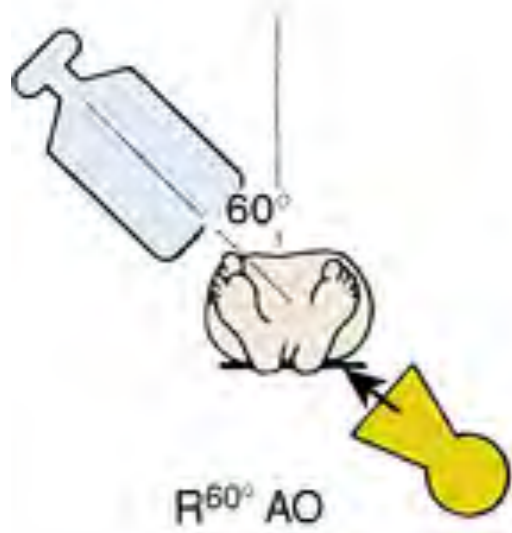
Left coronary artery



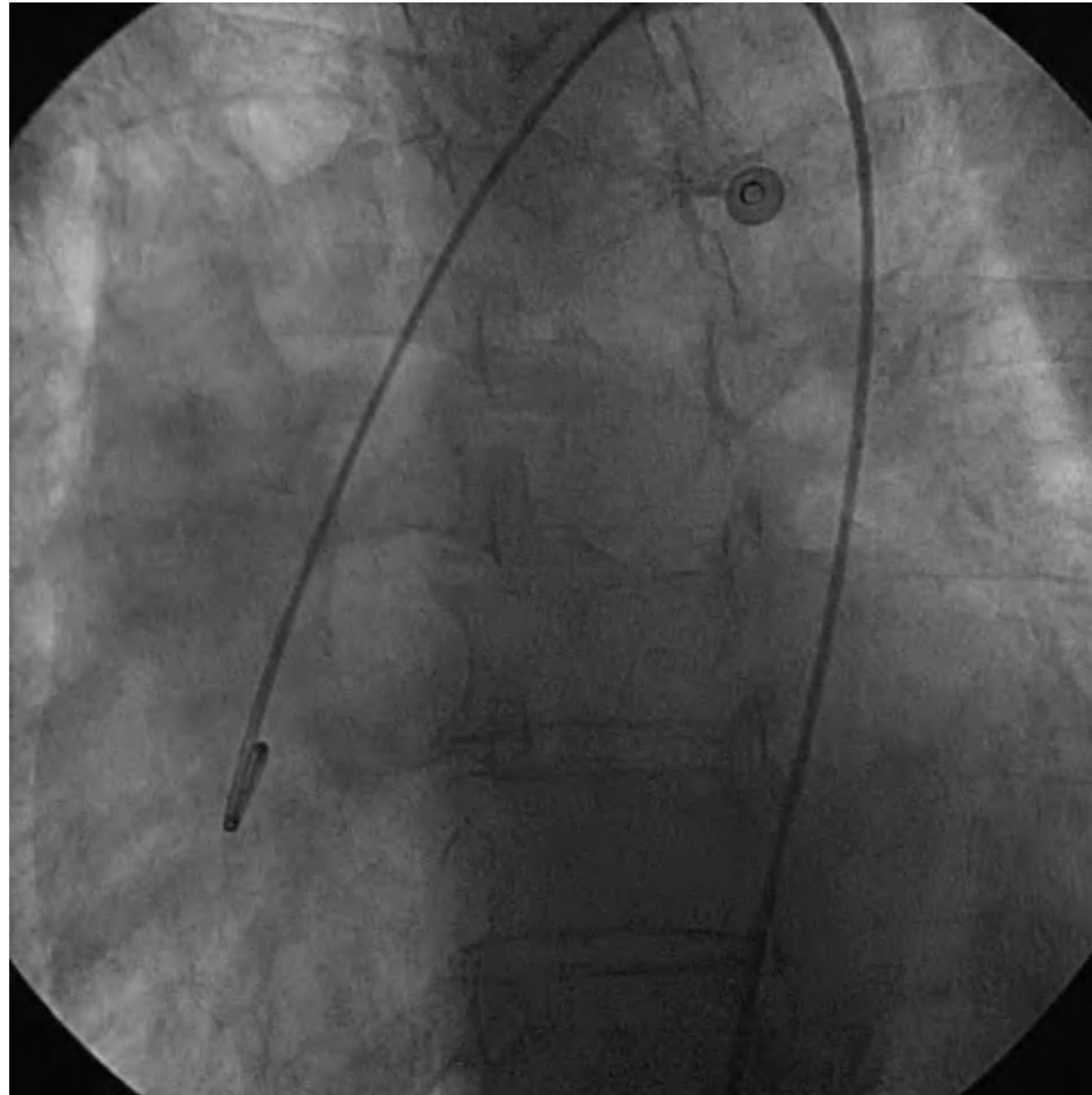
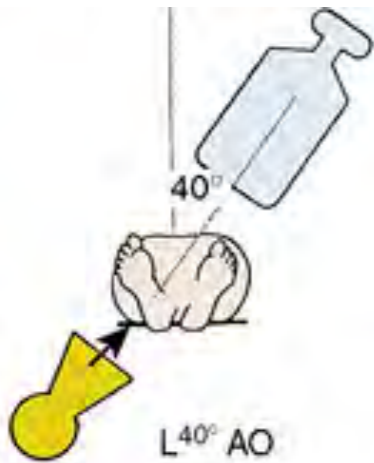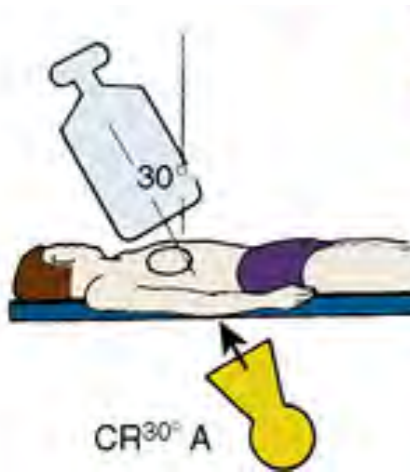Spider

Standard projection for main left coronary artery

Ventriculography

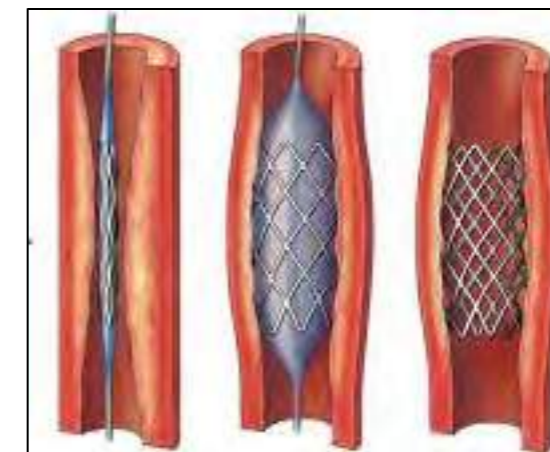

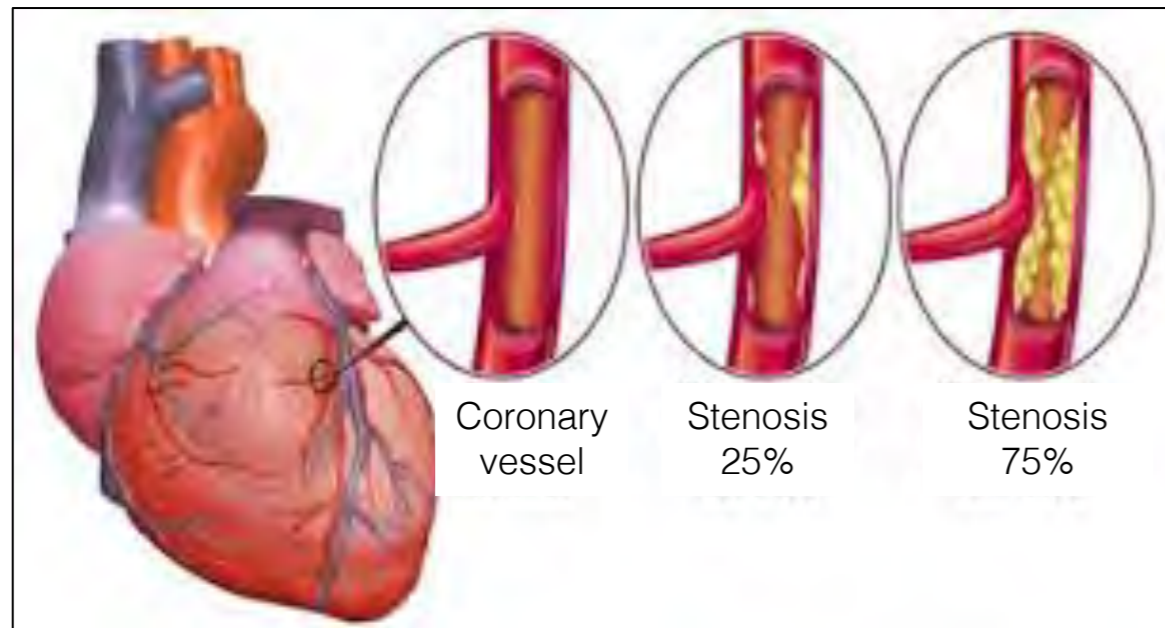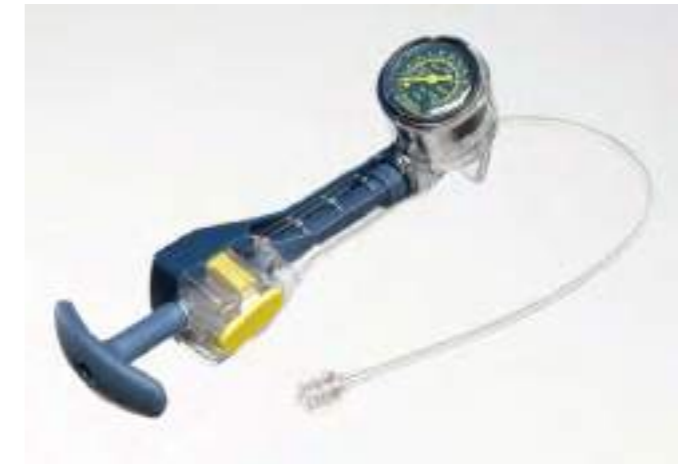


Aortography



LAO 30° - CRA 10°

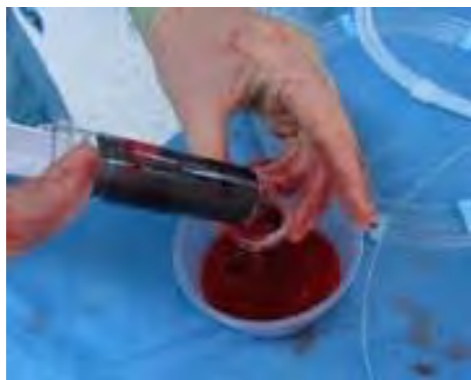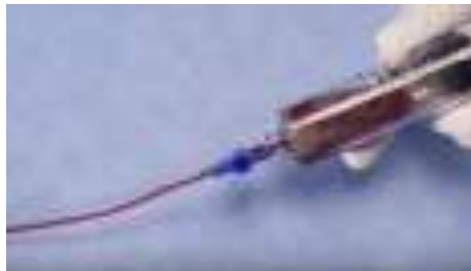Coronarography



Angioplasty

Angioplasty

Thromboaspiration

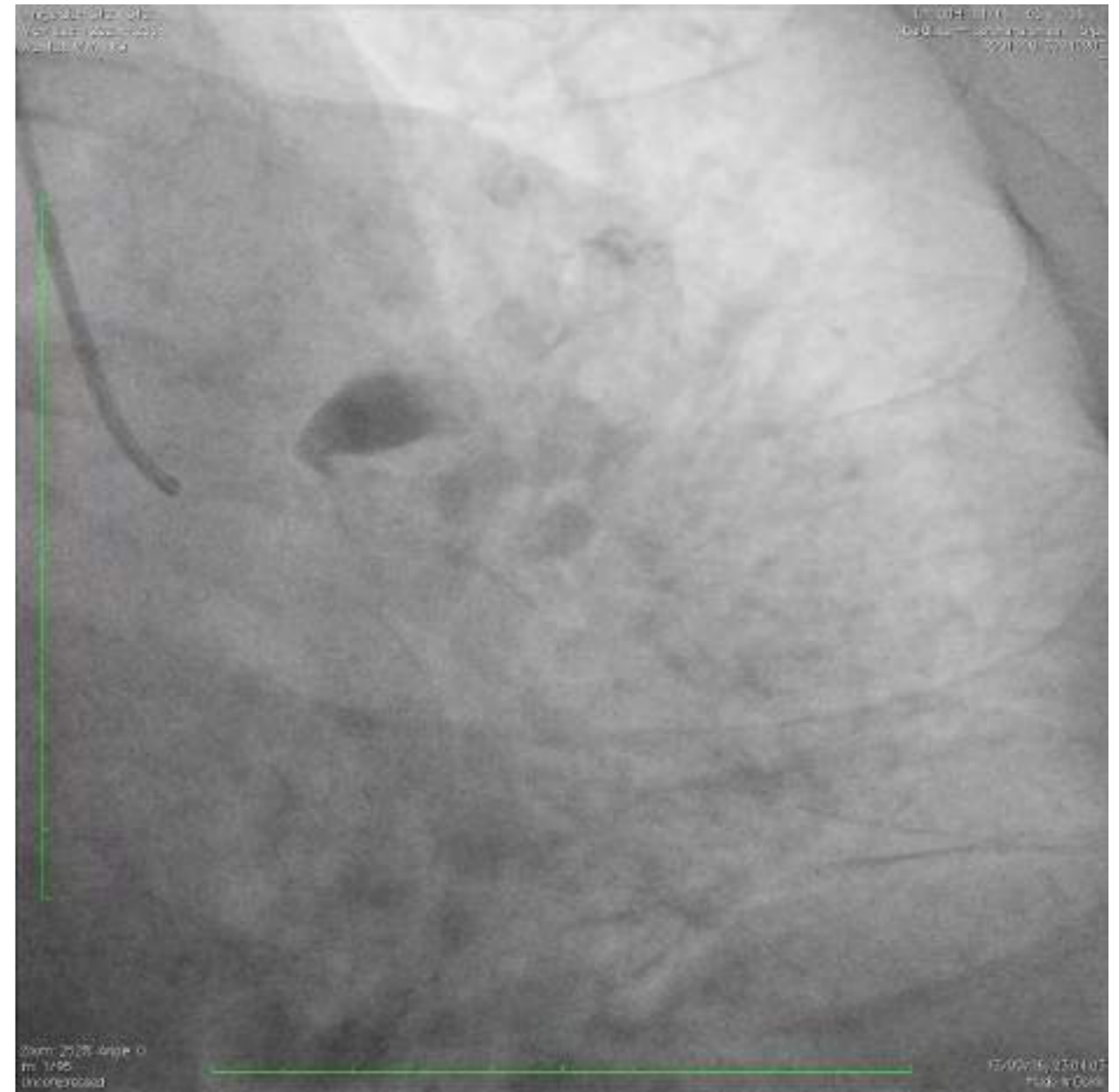
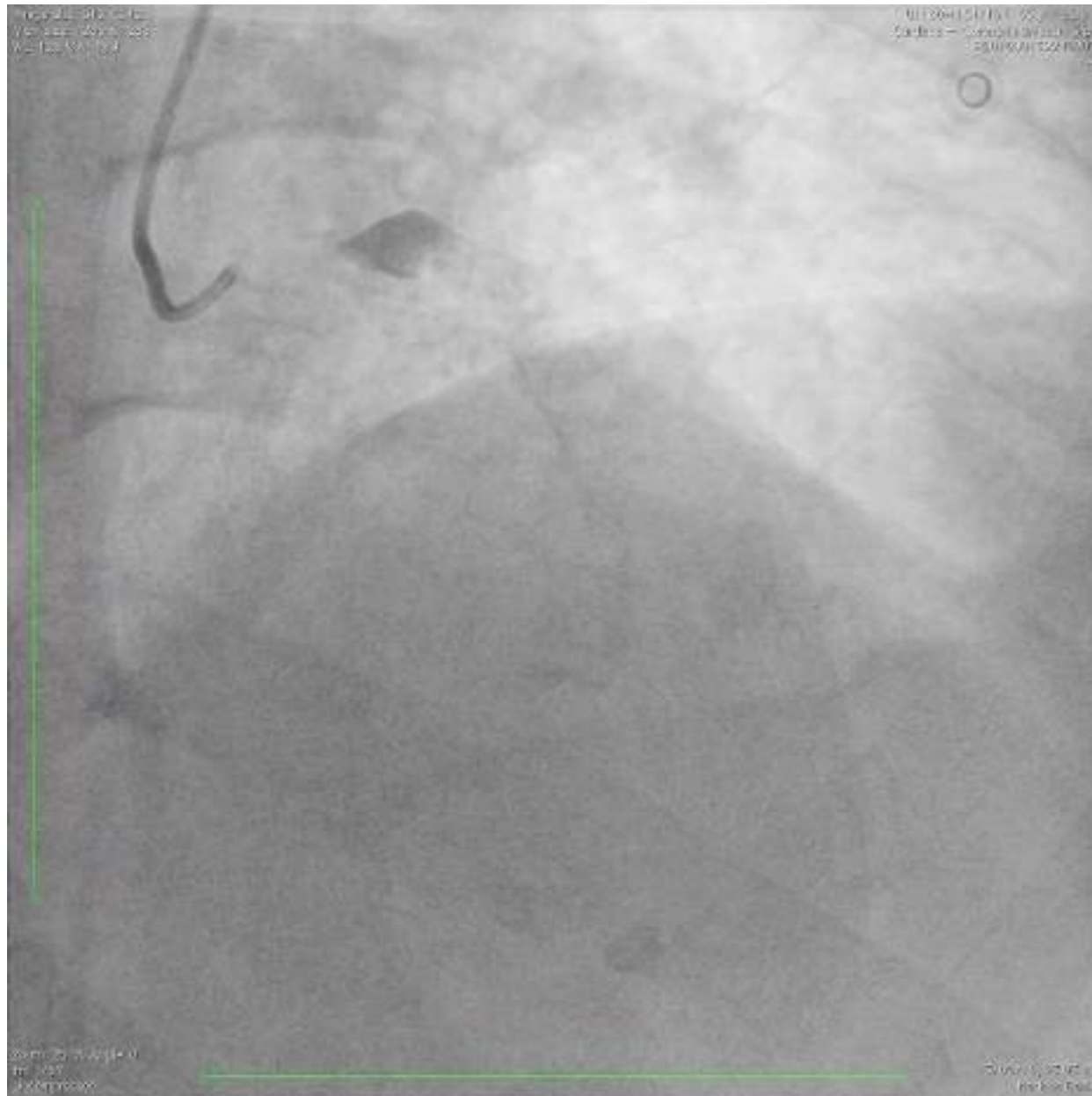
manual

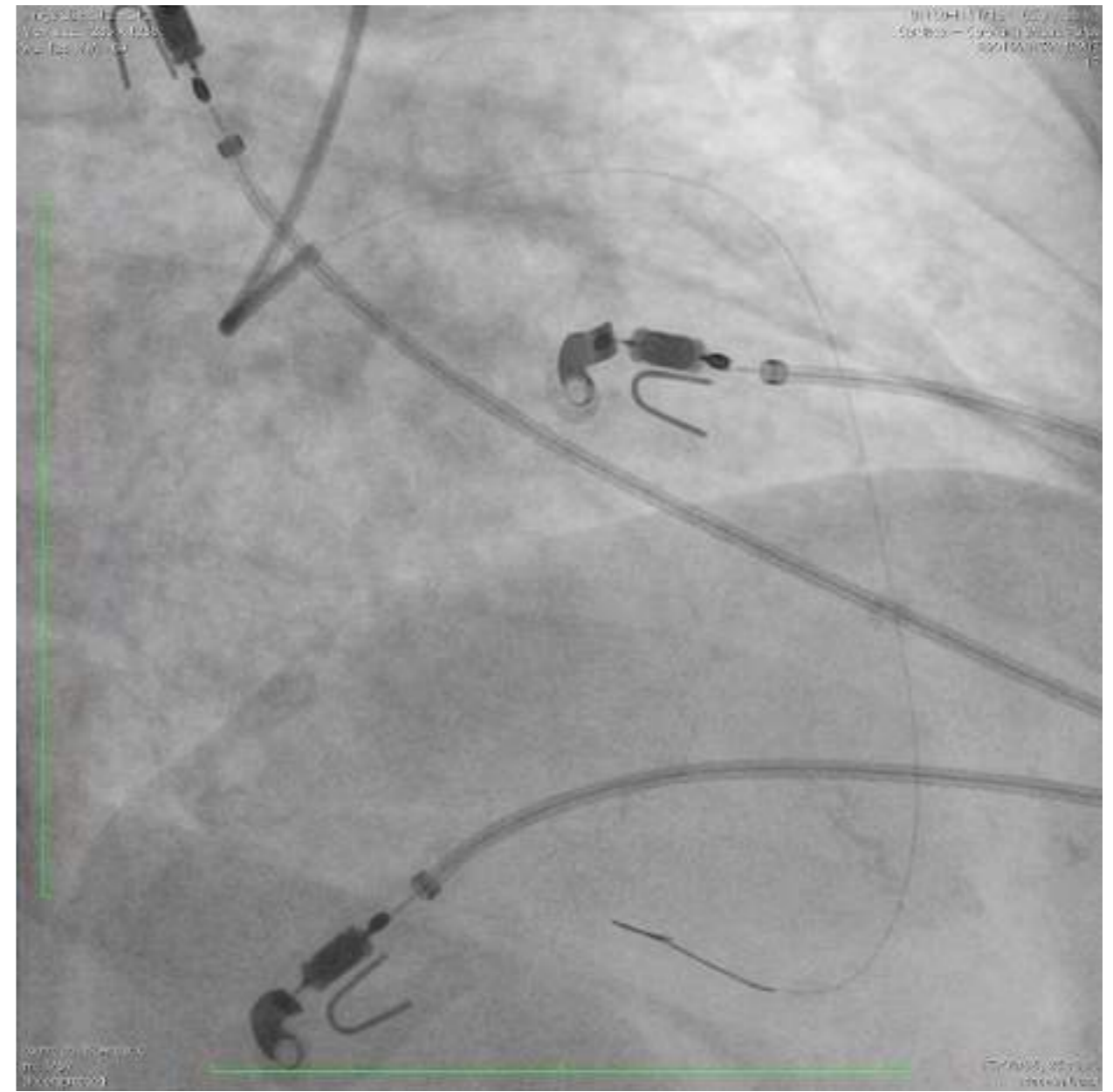
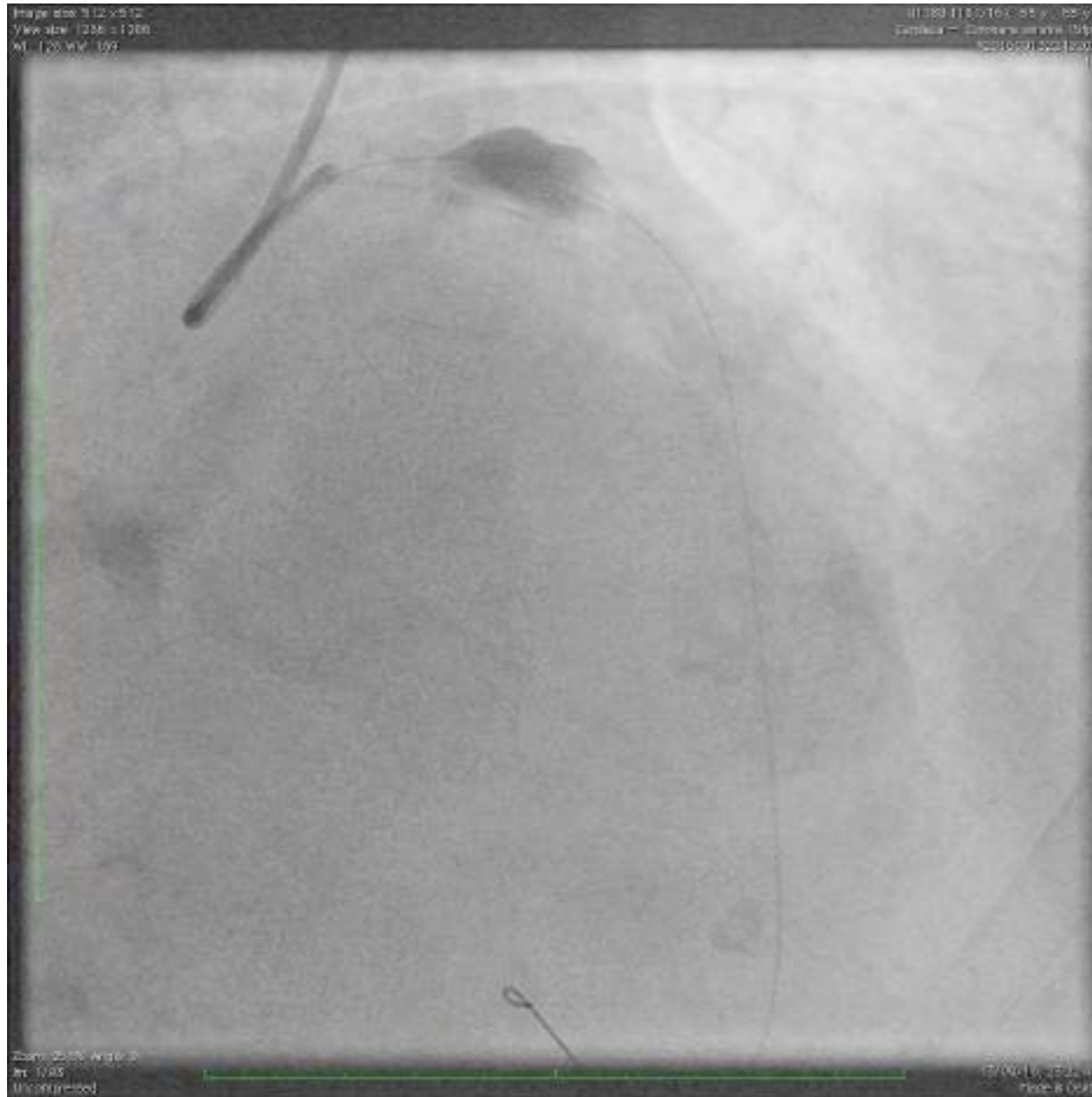
Angiojet

Angioplasty

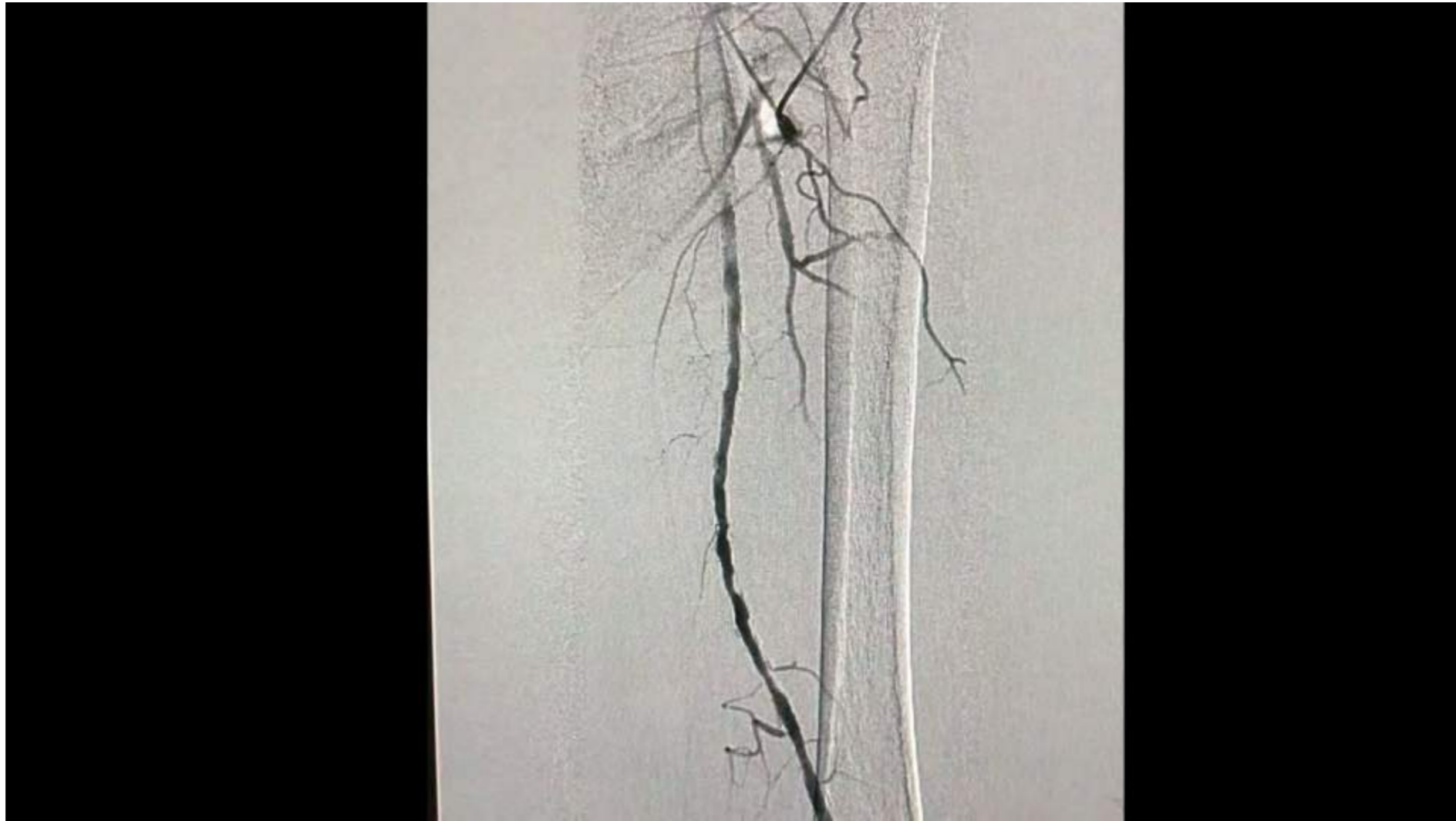

Angioplasty




IVA after
thromboaspiration

Peripheral Angioplasty



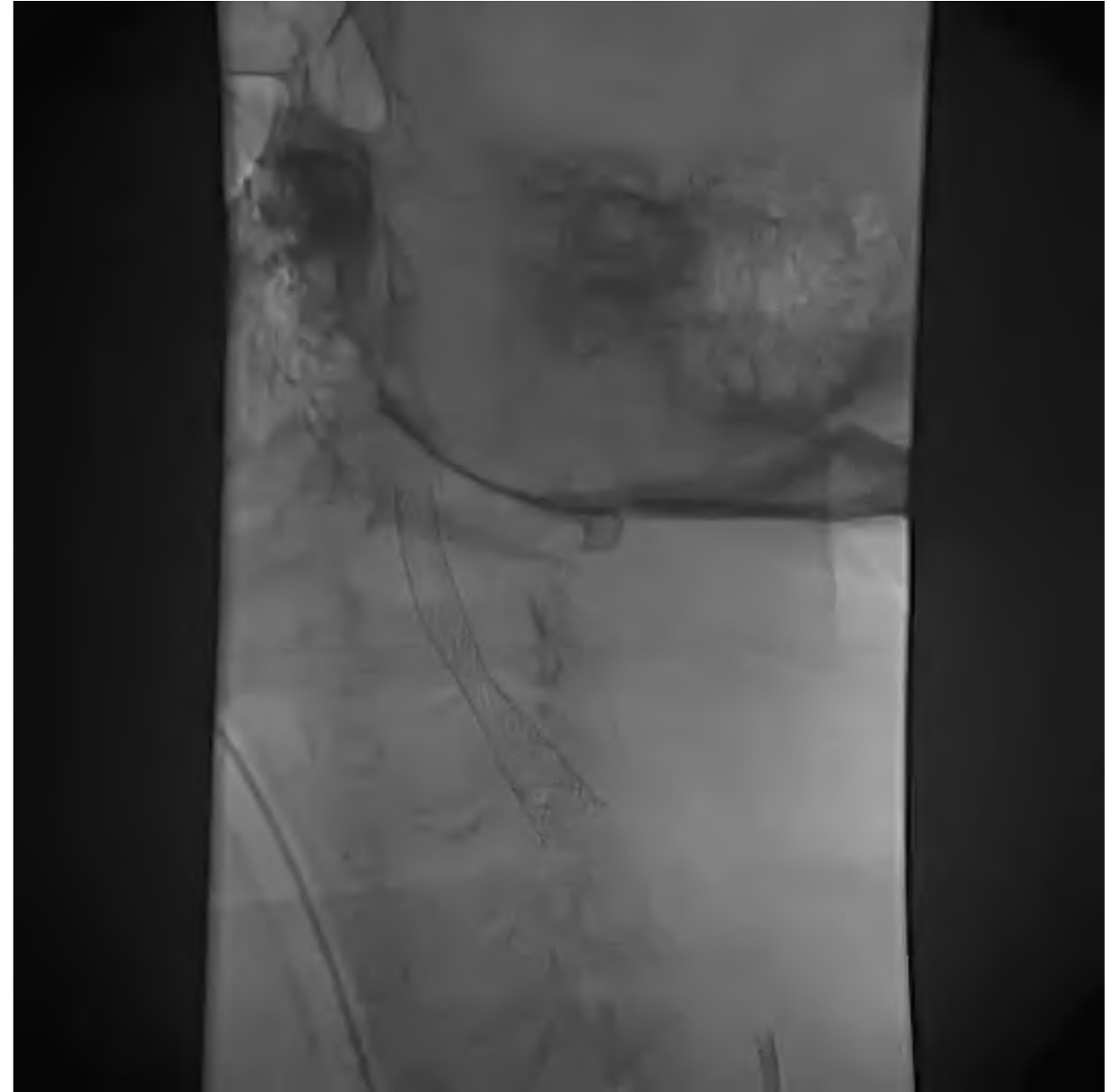
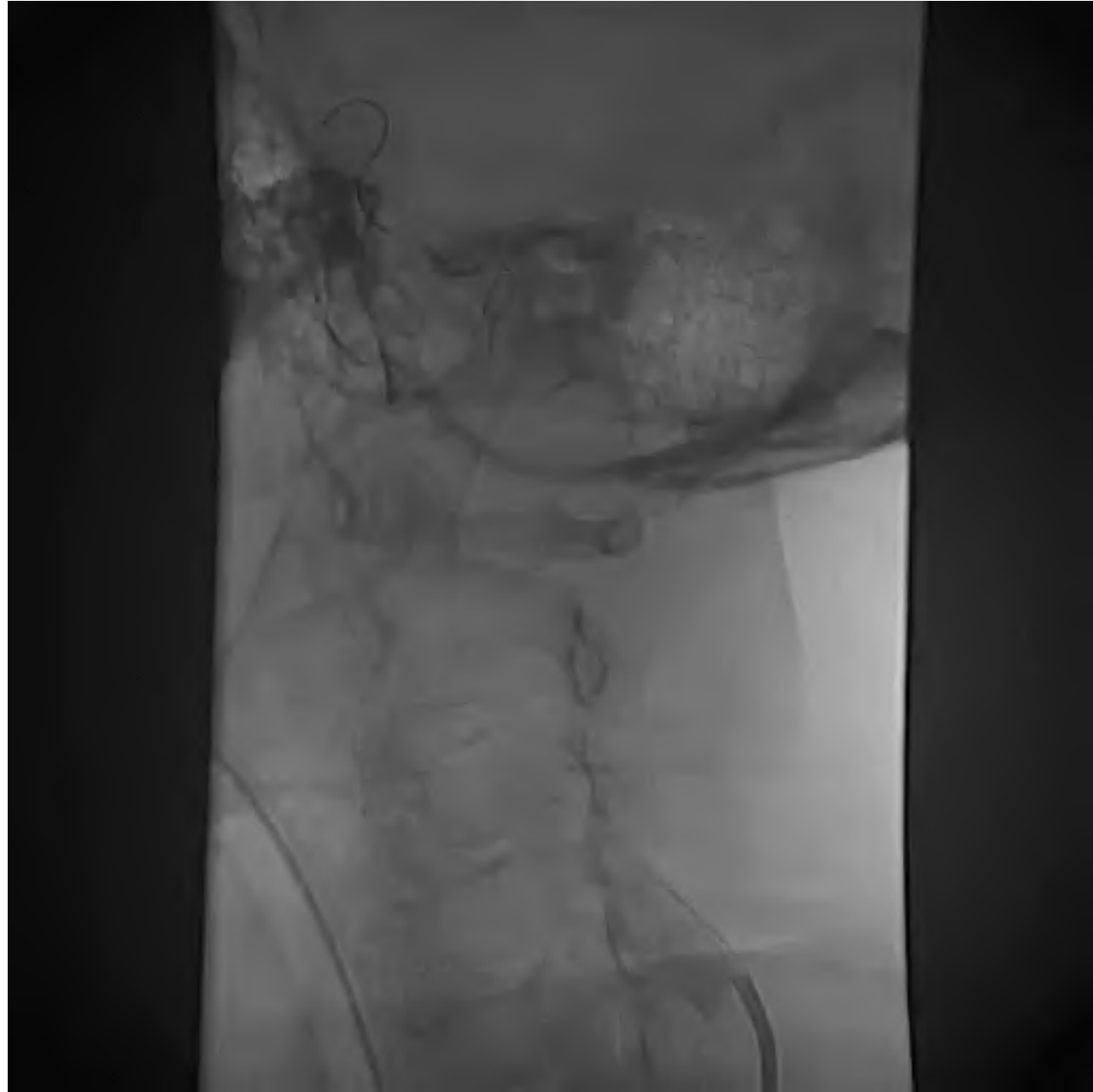
superficial femoral artery

Peripheral Angioplasty



Posterior tibial artery

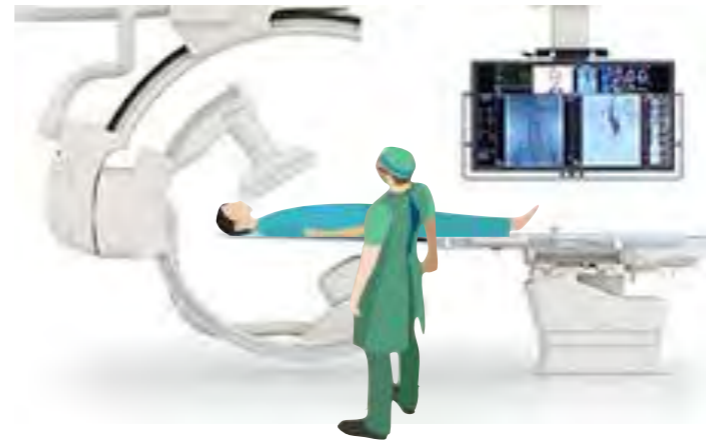Stenting in carotid artery





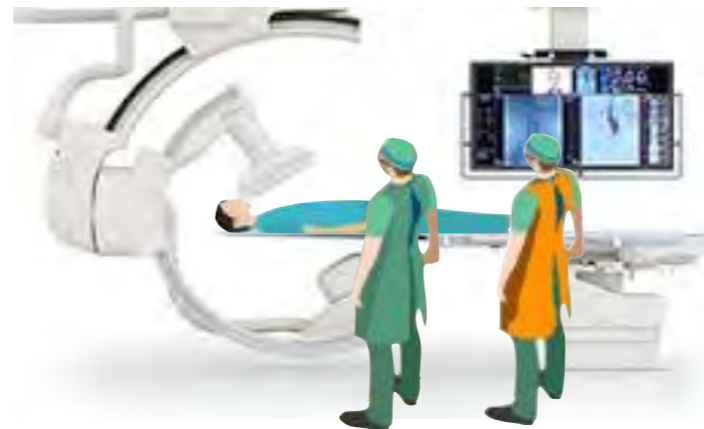Staff in Cath Lab

Cath Lab Y



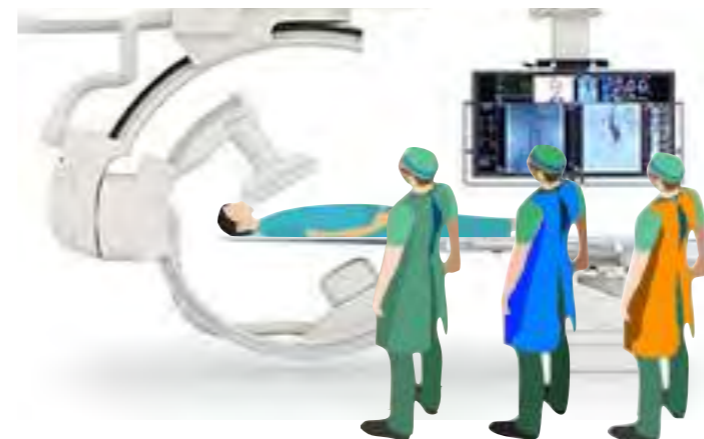Doctor

Cath Lab Arezzo



Nurse


Cath Lab X



Radiology Technician

The presence of radiology technician next to the doctor during procedures in Cath Lab reduce radiation exposure (50% of total DAP) and time procedure (30%).

A third operator does not improve the management of work.



Smart guide to reduce radiation

1. Take two steps back from the table during imaging
2. Use proper positioning of the C-arm in relation to the patient
3. Use lead drapes under the patient table to reduce scatter radiation
4. Lower the frame rate on the imaging system
5. Use more supplemental imaging like optical coherence tomography (OCT), intravascular ultrasound (IVUS) and transesophageal echo (TEE) instead of fluoro
6. Work with radiologist technician during procedure

Thanks for your attention!



Martina Nesti
S. Donato Hospital (Arezzo)
30/01/2020